

COVID-19: case 3

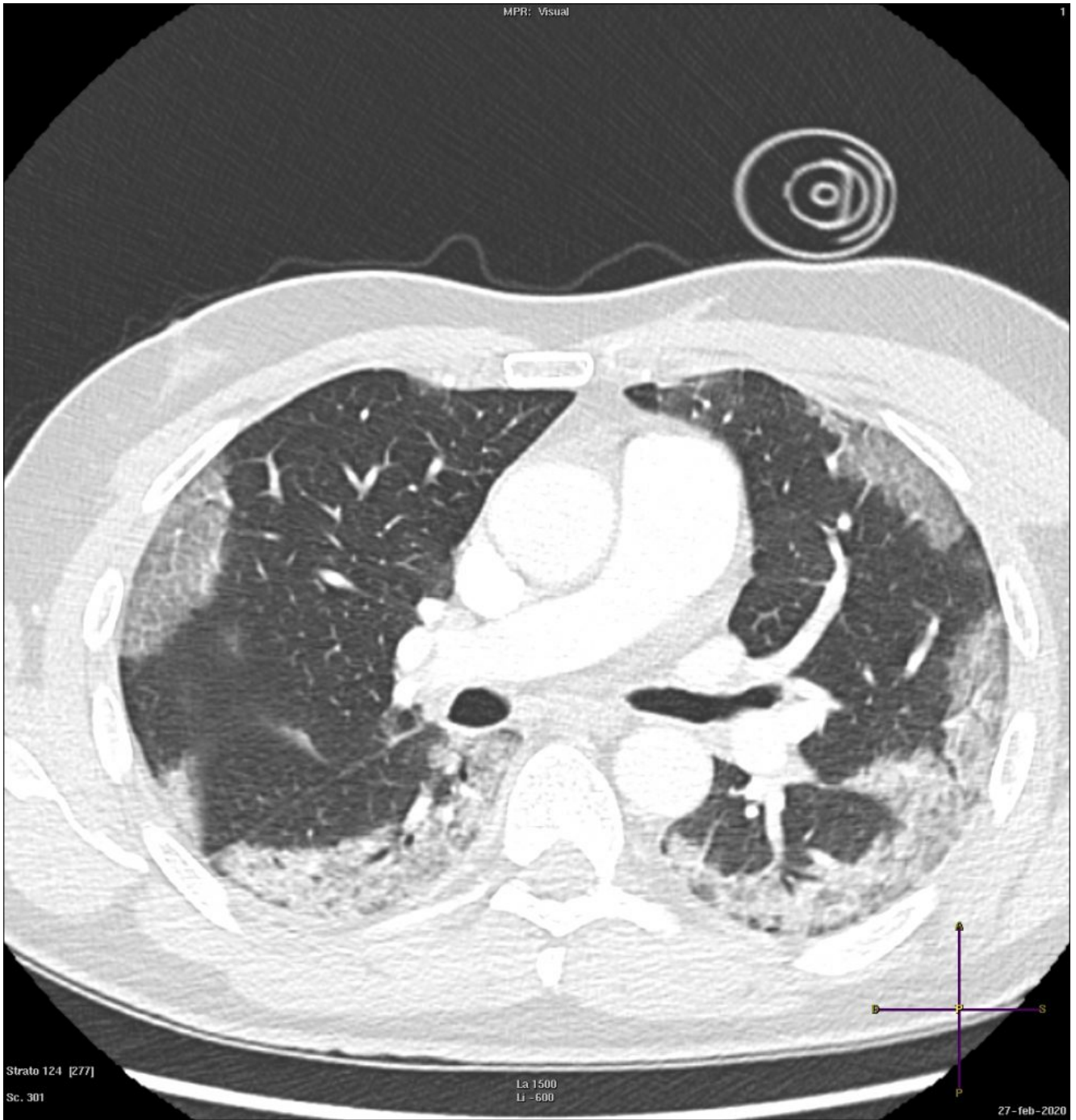
Radiologia ASST Cremona

57-year-old male patient with fever, cough. No previous medical history. Potential exposure to Covid-19 patients.

Respiratory

failure (hypoxemia and hypocapnia). Leukocitosi. Nasal swab positive for SARS-CoV-2.

HRCT

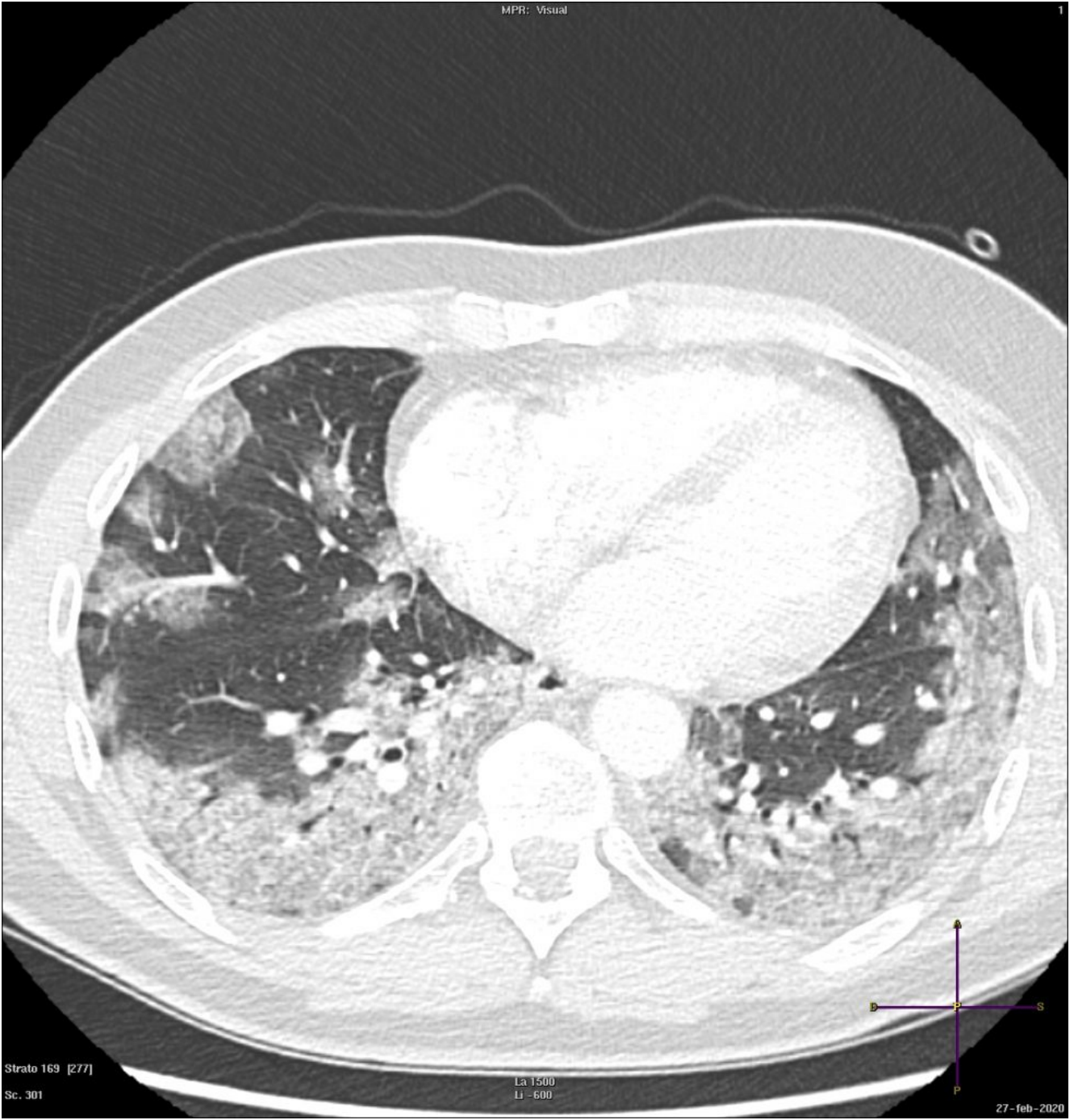


Strato 124 [277]

Sc. 301

La 1500
Li -600

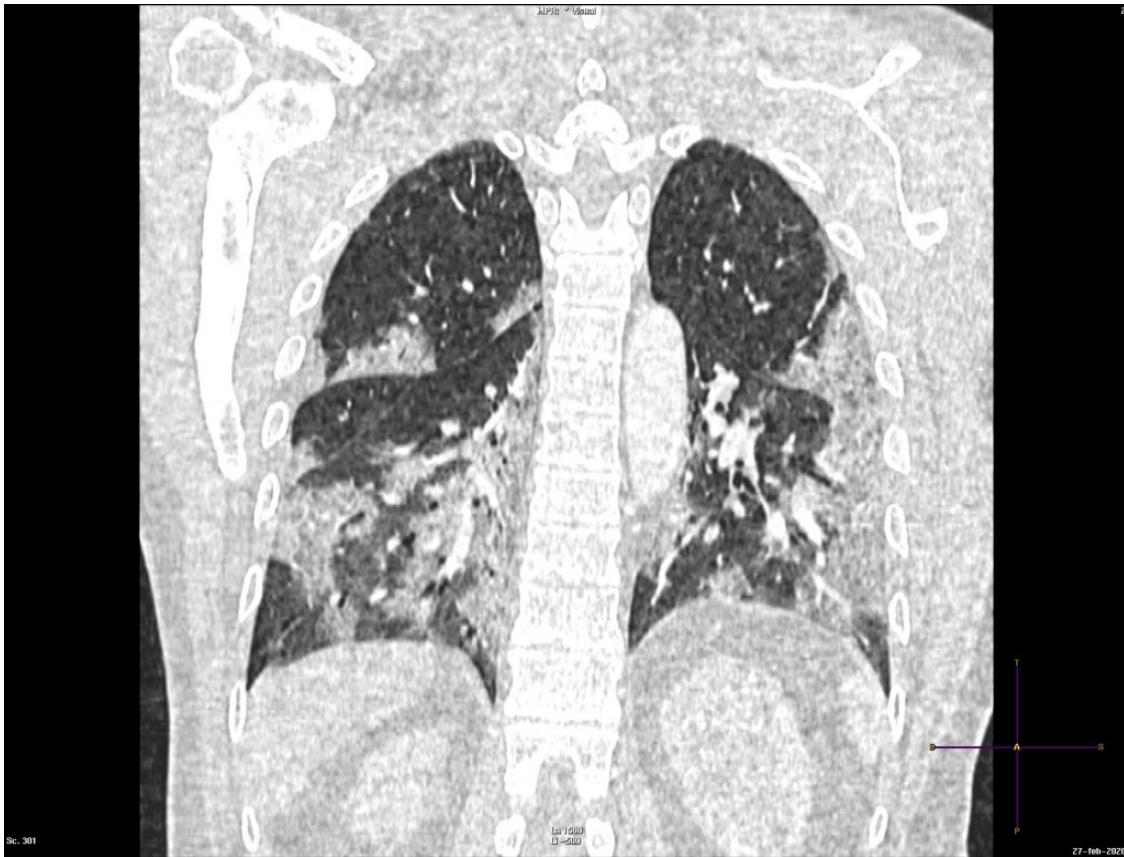27-feb-2020



Strato 169 [277]
Sc. 301

La 1500
Li -600

27-feb-2020



Subpleural ground-glass opacity with predominant subpleural distribution and consolidations in all lobes, particularly in the lower lobes.