

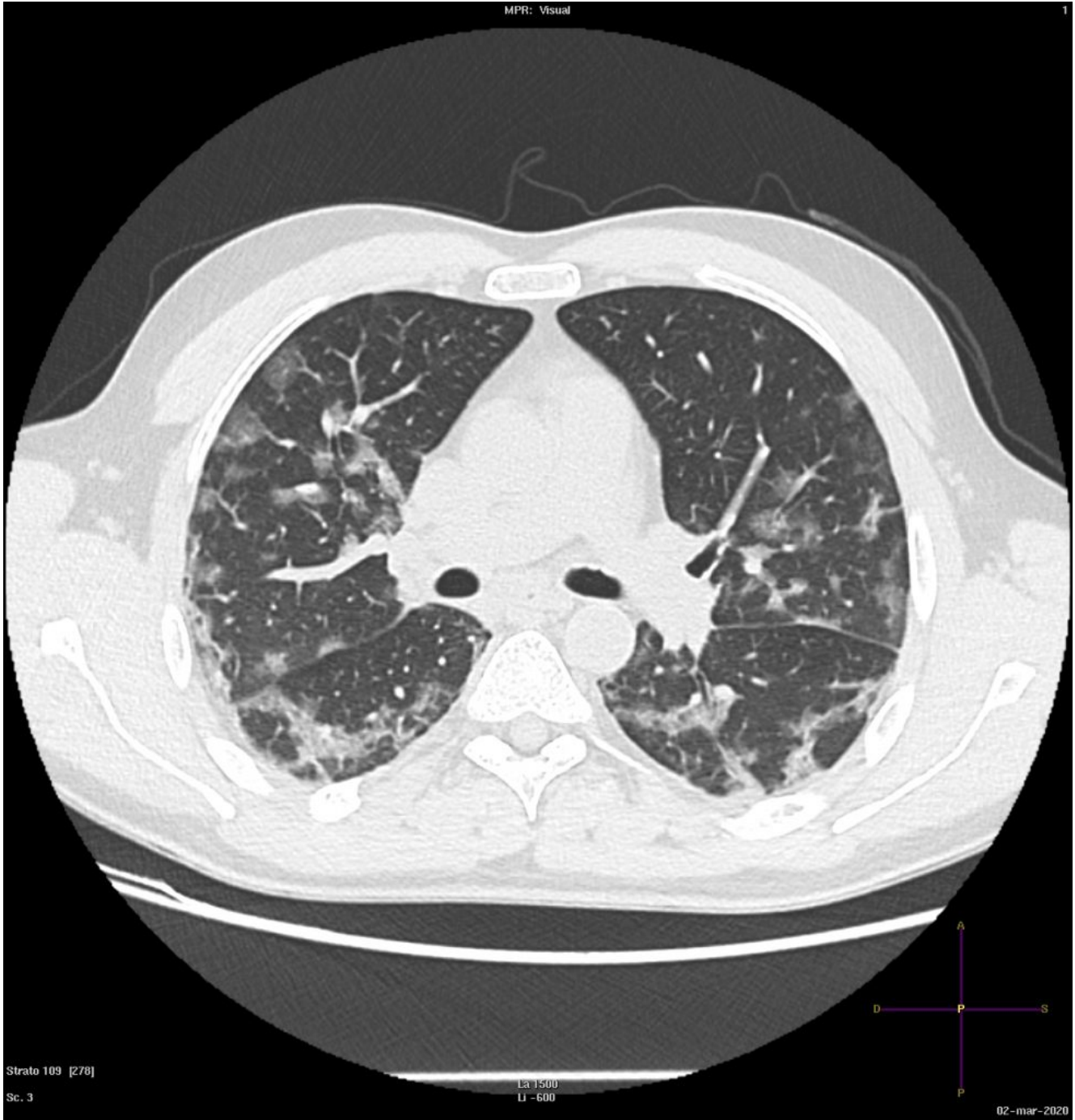
COVID-19: case 4

Radiologia ASST Cremona

45-year-old male
patient with fever, cough. No previous medical history.
Potential exposure to
Covid-19 patients.

Respiratory failure (hypoxemia and hypocapnia). Leukopenia.
Nasal swab positive for SARS-CoV-2.

HRCT

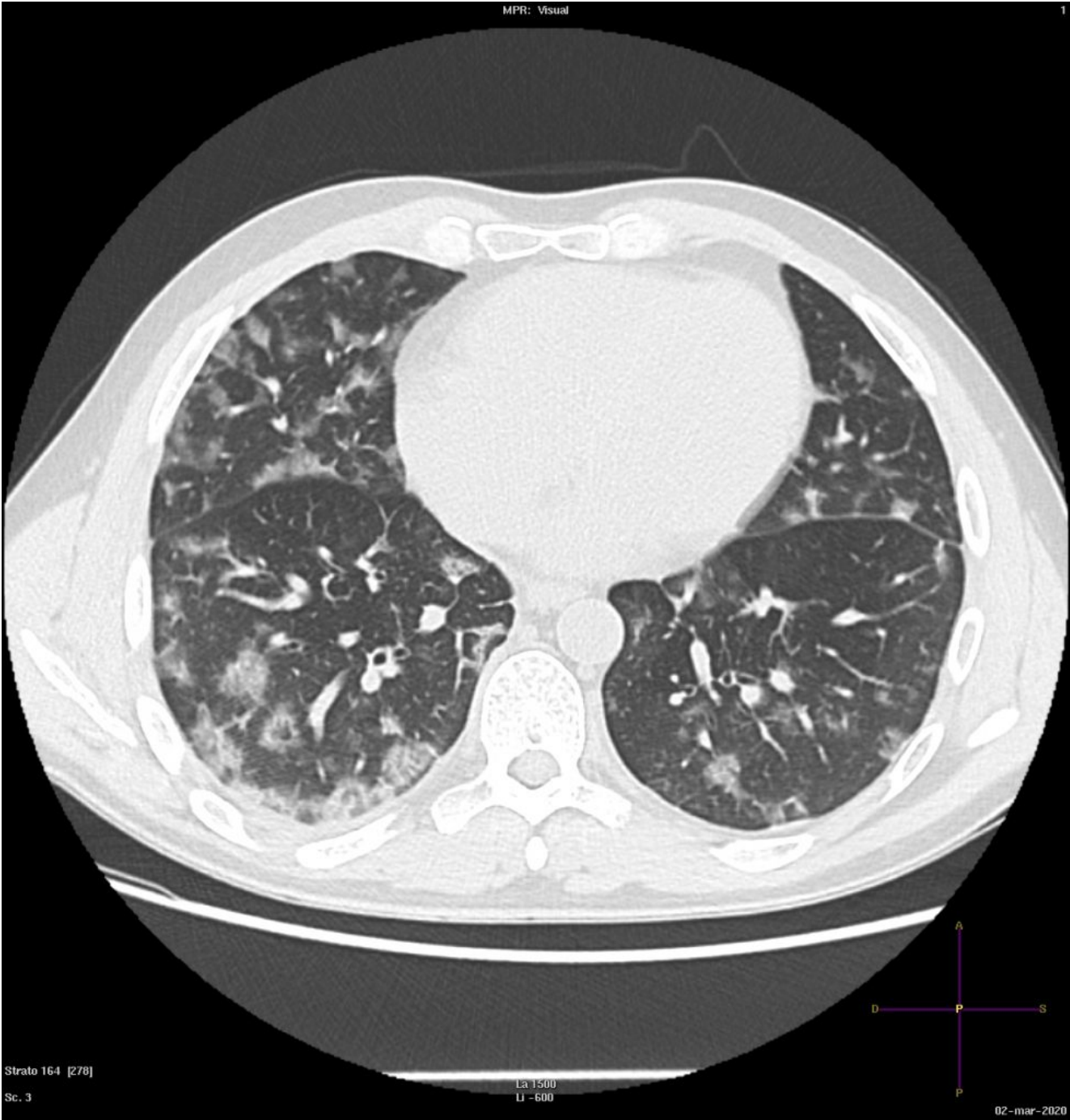


Strato 109 [278]

Sc. 3

LA 1500
LI -600

02-mar-2020



Strato 164 [278]
Sc. 3

La 1500
LI -600

02-mar-2020

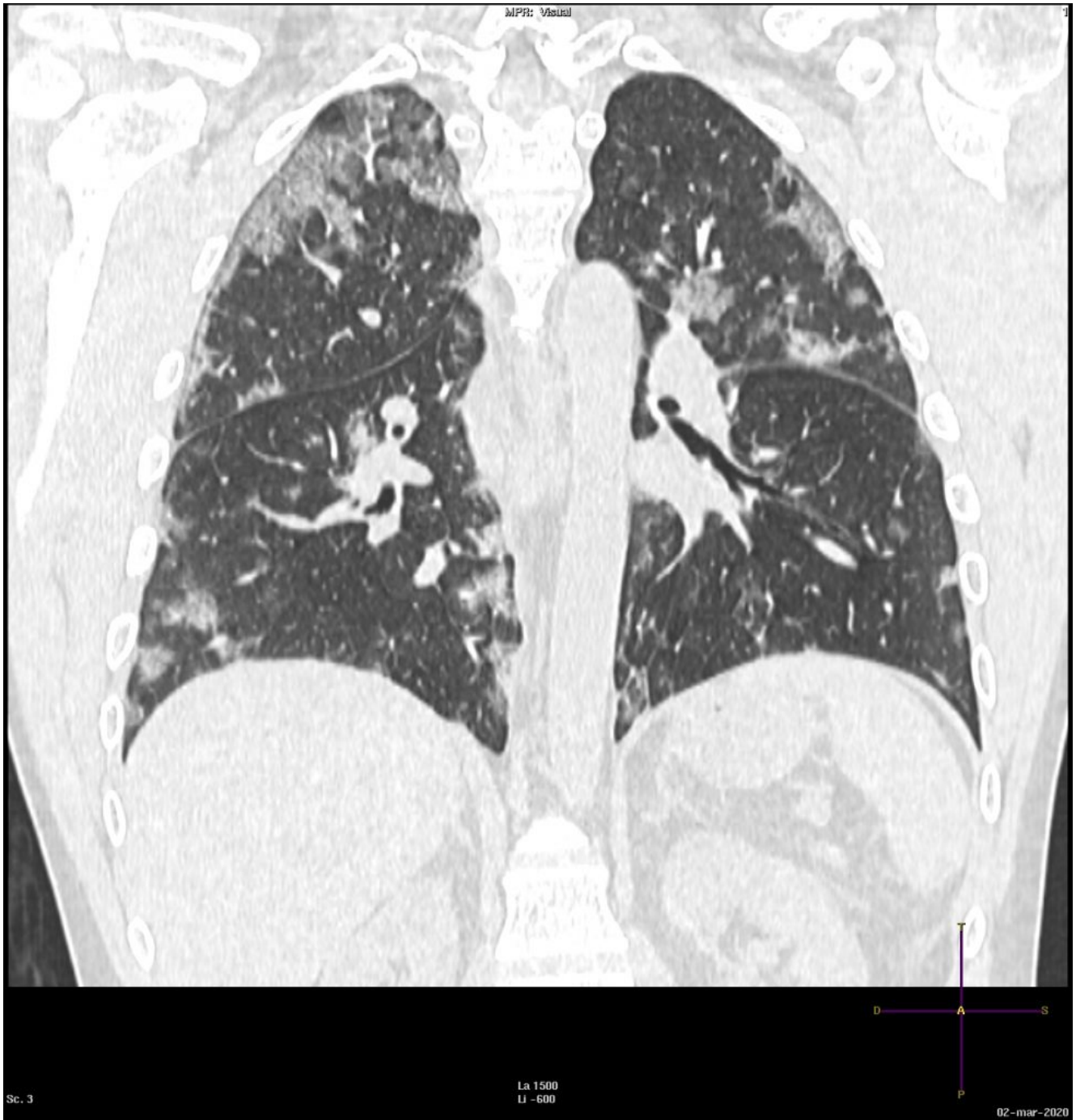
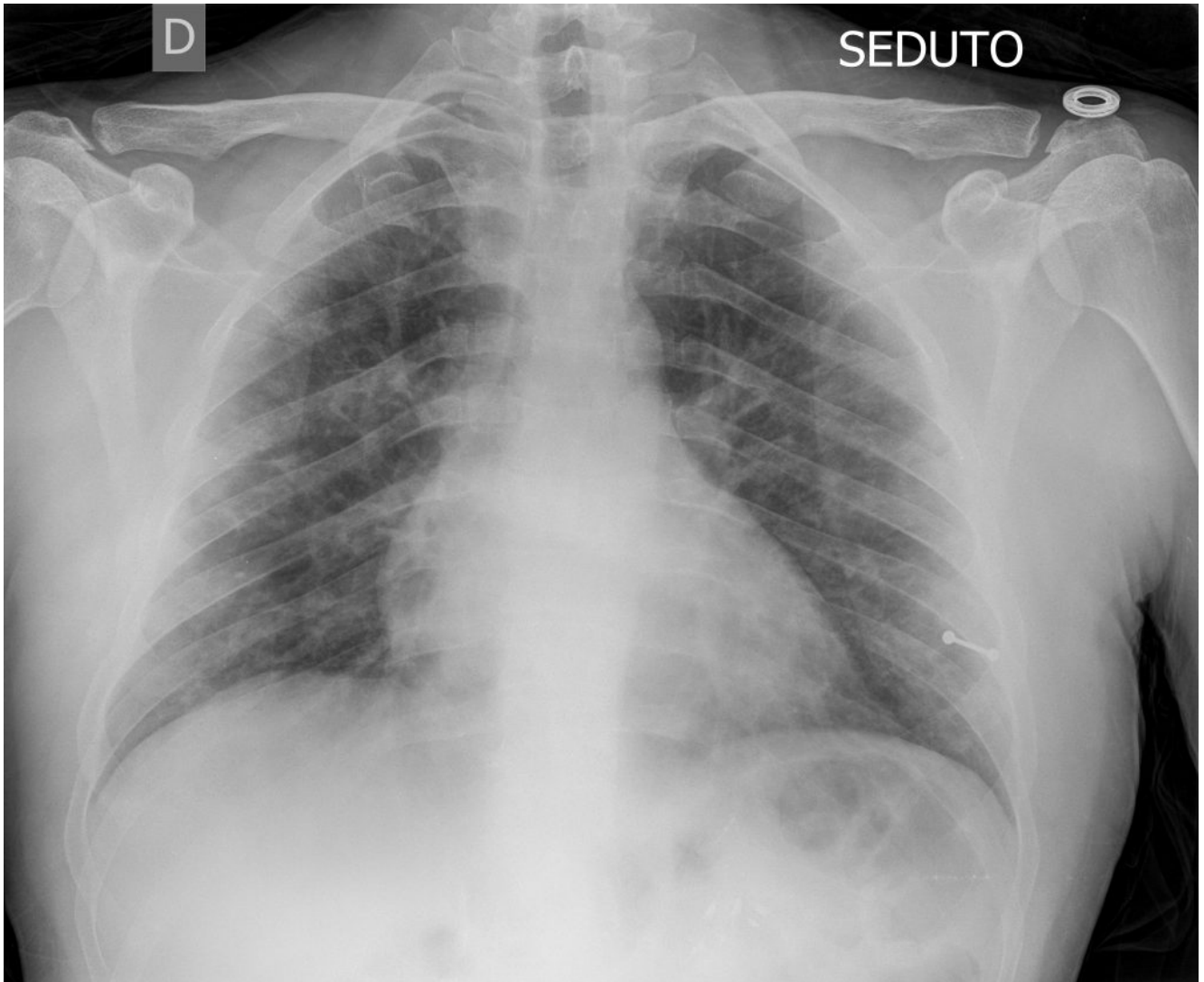


Figura 3

Multiple diffuse ground-glass opacities in all lobes, with random distribution, predominant subpleural and peribronchial in the upper lobes

Chest film (for comparison)



Small, blurred bilateral opacities.