

# COVID-19: case 5

Radiologia ASST Cremona

63-year-old male patient with no previous medical history. Exposure to Covid-19 patients. Fever, cough.

Respiratory failure (hypoxemia and hypocapnia). Leukocytosis. Nasal swab positive for SARS-CoV-2.

HRCT

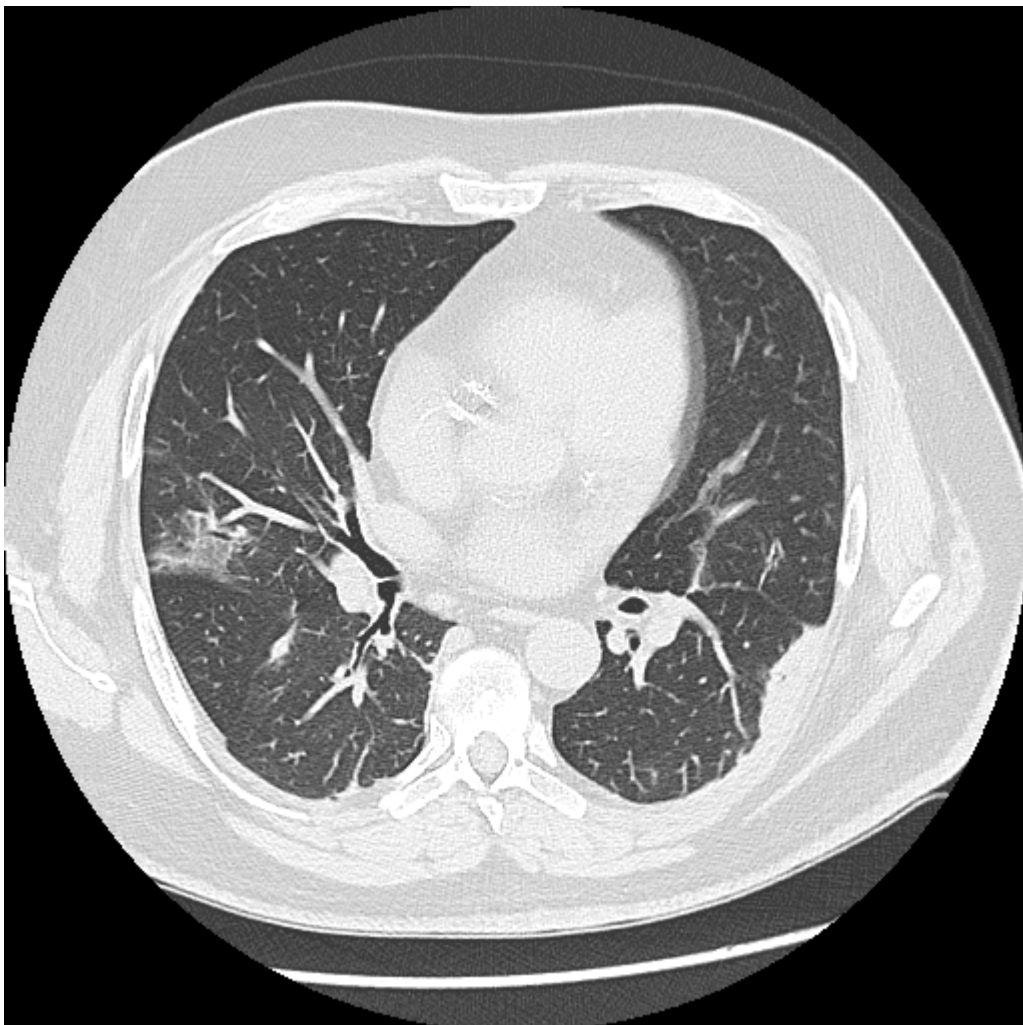


Figura 1

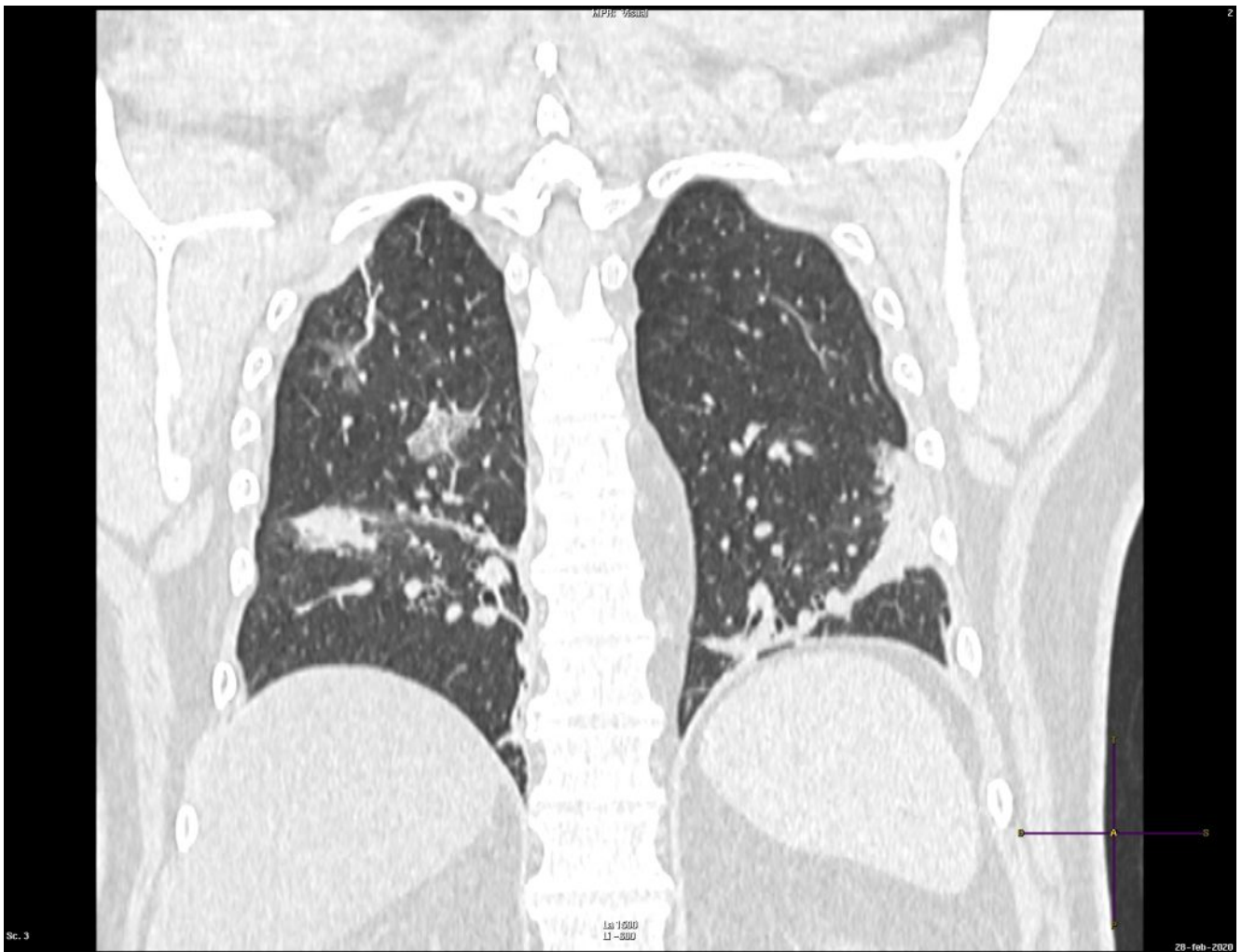

Figura 2

Fig.1-2: Ground-glass opacities in the RUL and RLL with consolidations in the lower lobes, especially in the LLL.

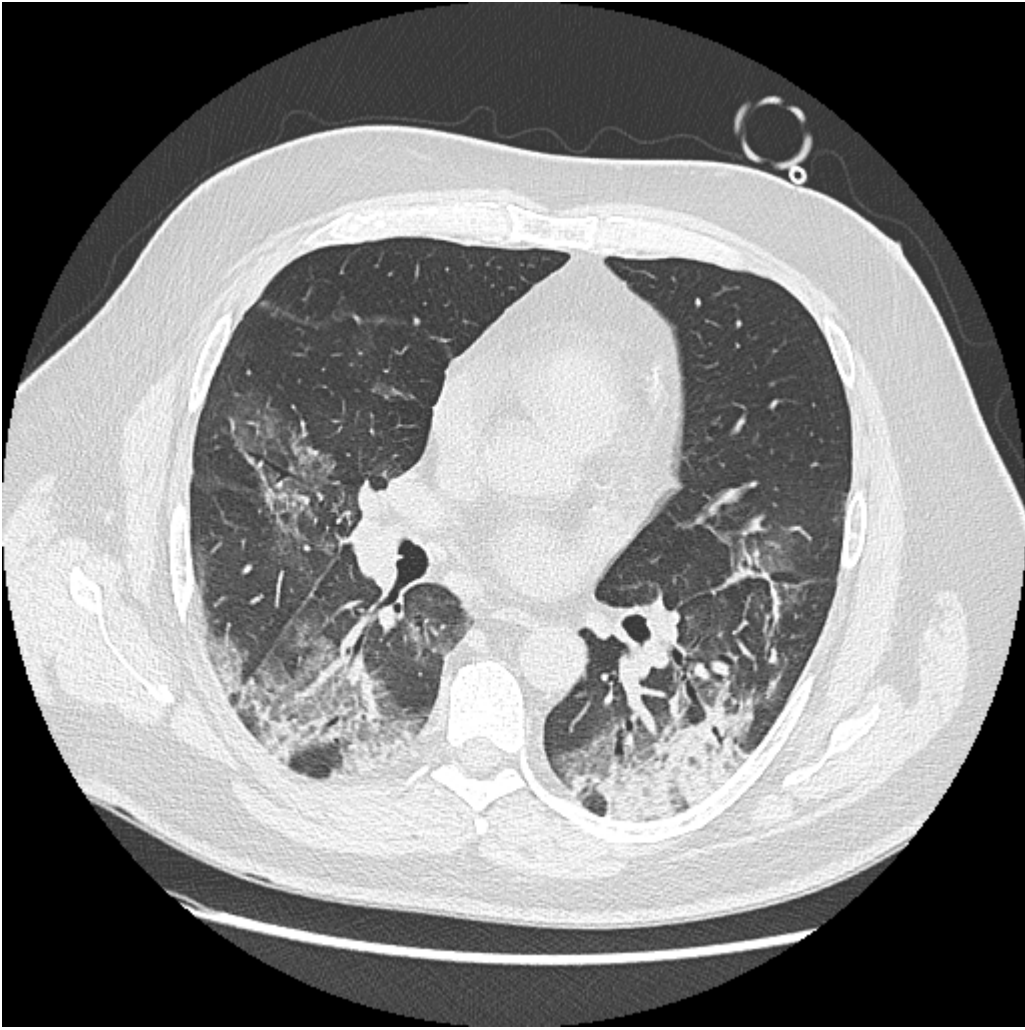


Figura 3

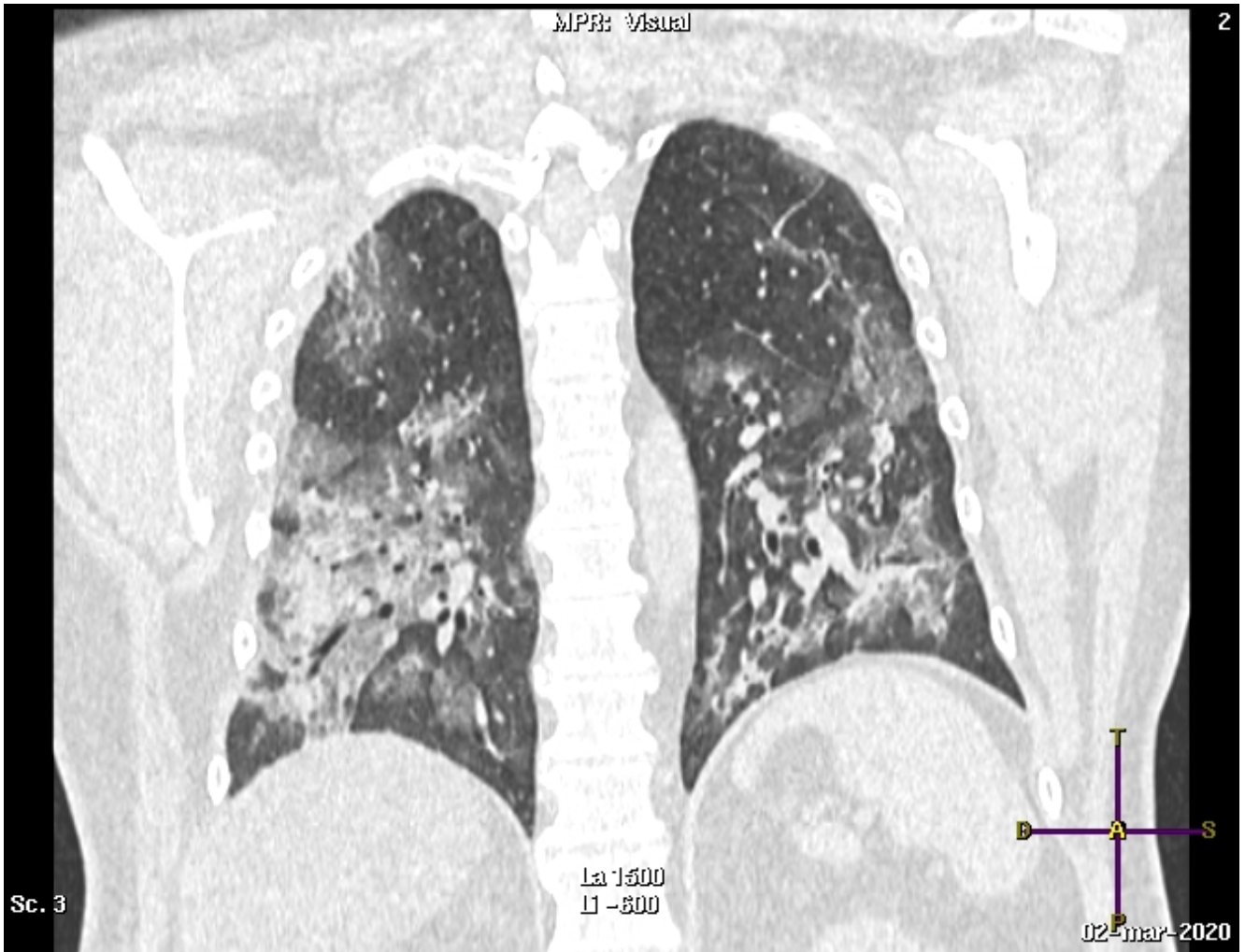


Figura 4

Fig. 3 – 4: The ground-glass opacities in the lower lobes are more extended and consolidations are also noted.