

COVID-19: case 1

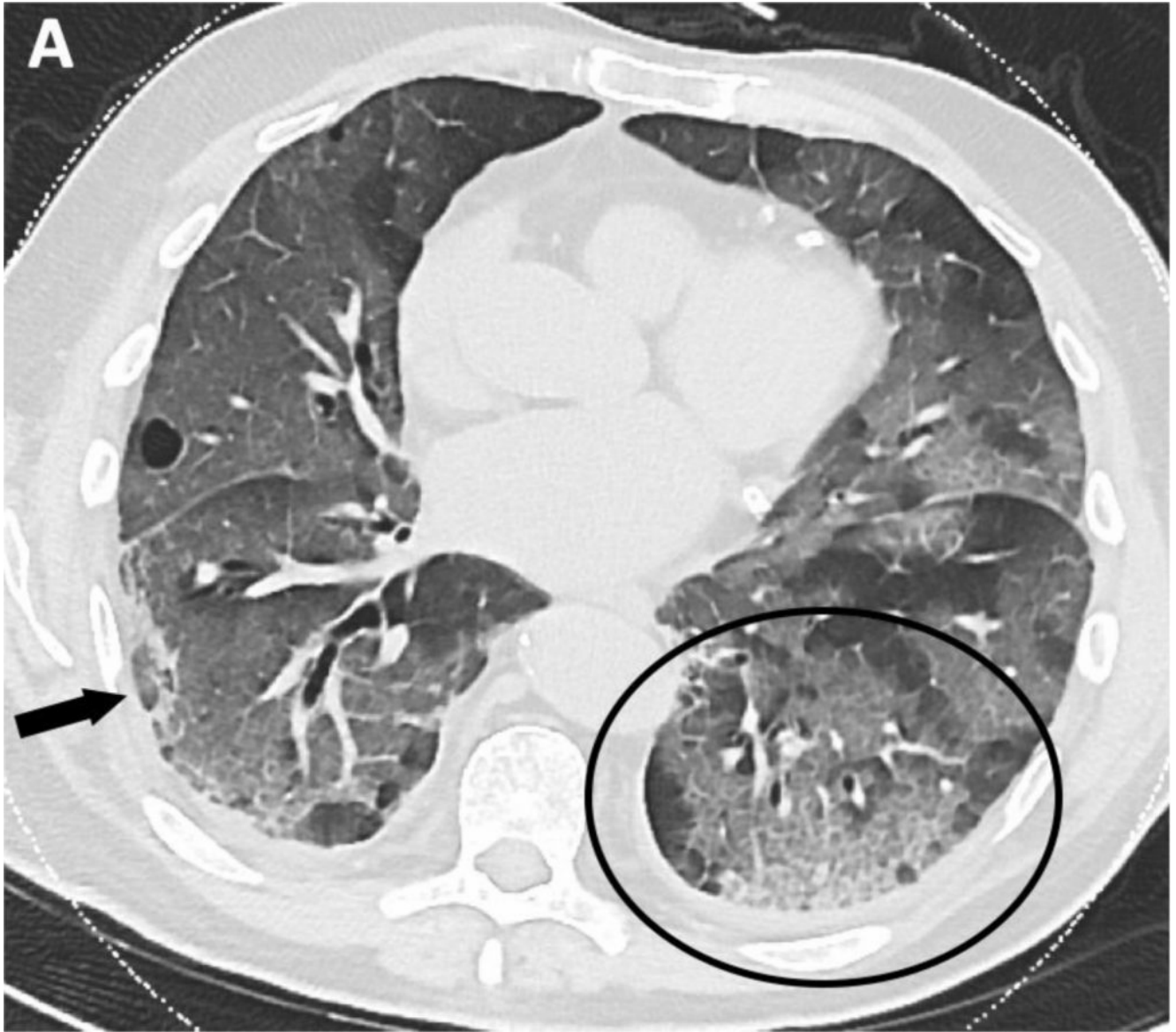
A. Borgheresi, A. Agostini, L. Ottaviani, C. Floridi, A. Giovagnoni

Dipartimento di Scienze Radiologiche – Scuola di Specializzazione in Radiologia

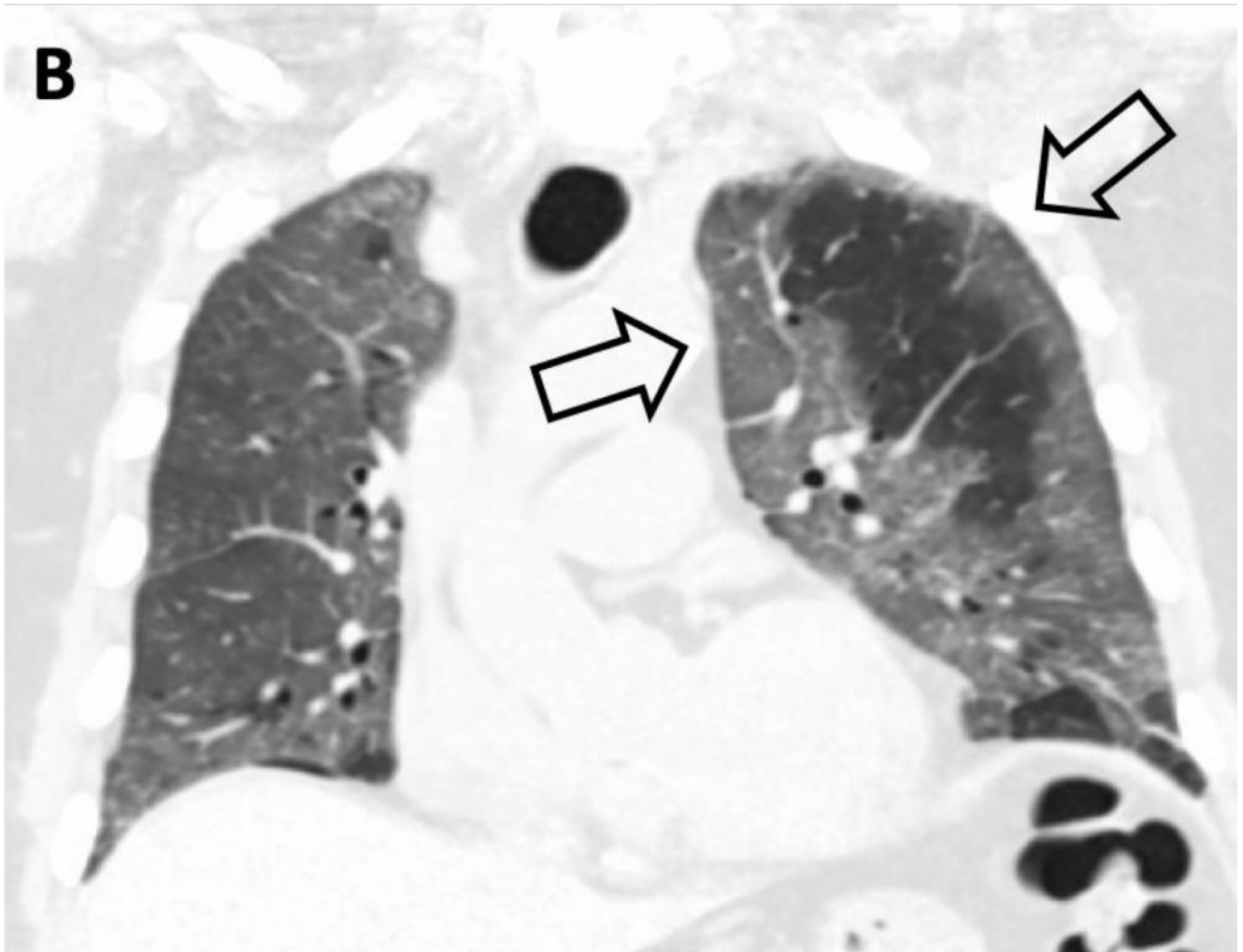
Università Politecnica delle Marche – Azienda Ospedali Riuniti – Torrette – Ancona

80-year-old male patient with fever and dyspnea. Nasal swab positive for SARS-CoV-2.

HRCT



Multiple ground-glass opacities associated with reticulations in a “crazy-paving pattern” (black circle) – particularly in the lower lobes. Subpleural consolidation (black arrow).



In the coronal view, the peripheral distribution of the GGOs is seen (arrows)