

COVID-19: case 56

Gallarato Gabriele, Demaria Paolo, Negri Alberto, Baralis Ilaria, Cerutti Andrea, Priotto Roberto, Violino Paolo.

S.C. Radiodiagnostica – A.O. “S. Croce e Carle” – Cuneo

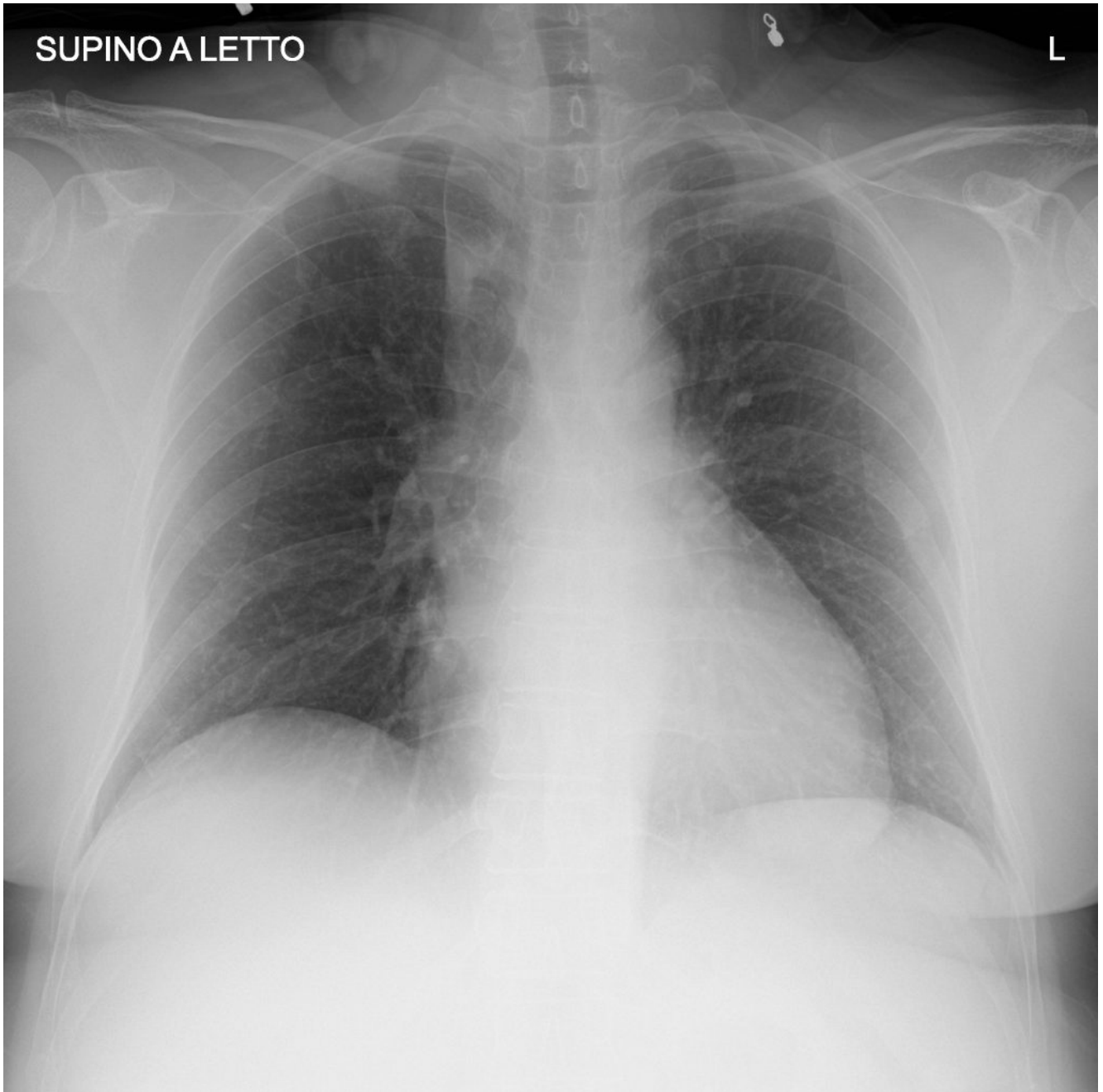
53-year-old female

patient with fever and malaise for 4 days, in clinical worsening. The patient was admitted to ED for head and costal trauma after micturition syncope. Prior medical history: asthma in treatment with montelukast, beclomethasone and formoterol.

Blood test: C-RP 10.12 mg/L, Procalcitonin: 0,13 ng/ml, LDH: 279 U/L.

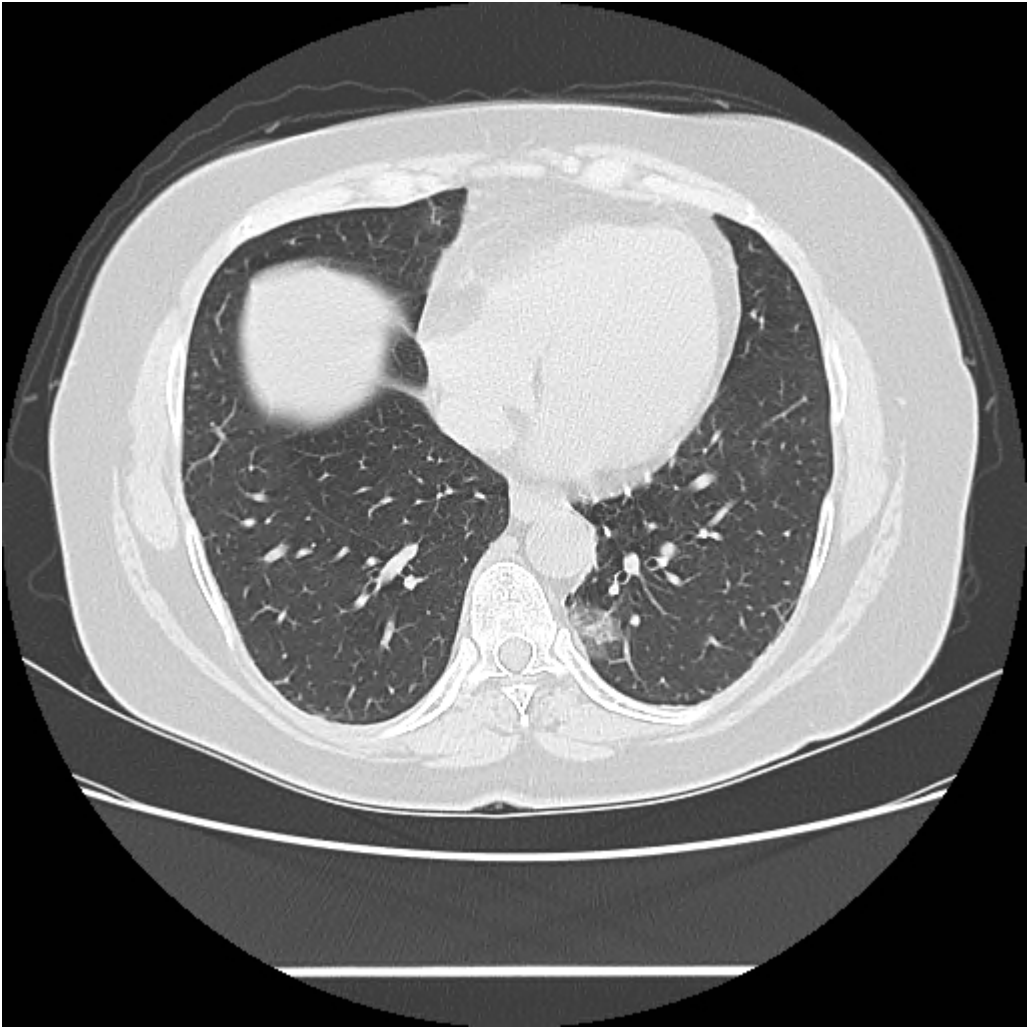
RT-PCR on a nasopharyngeal swab for SARS-CoV-2 was positive

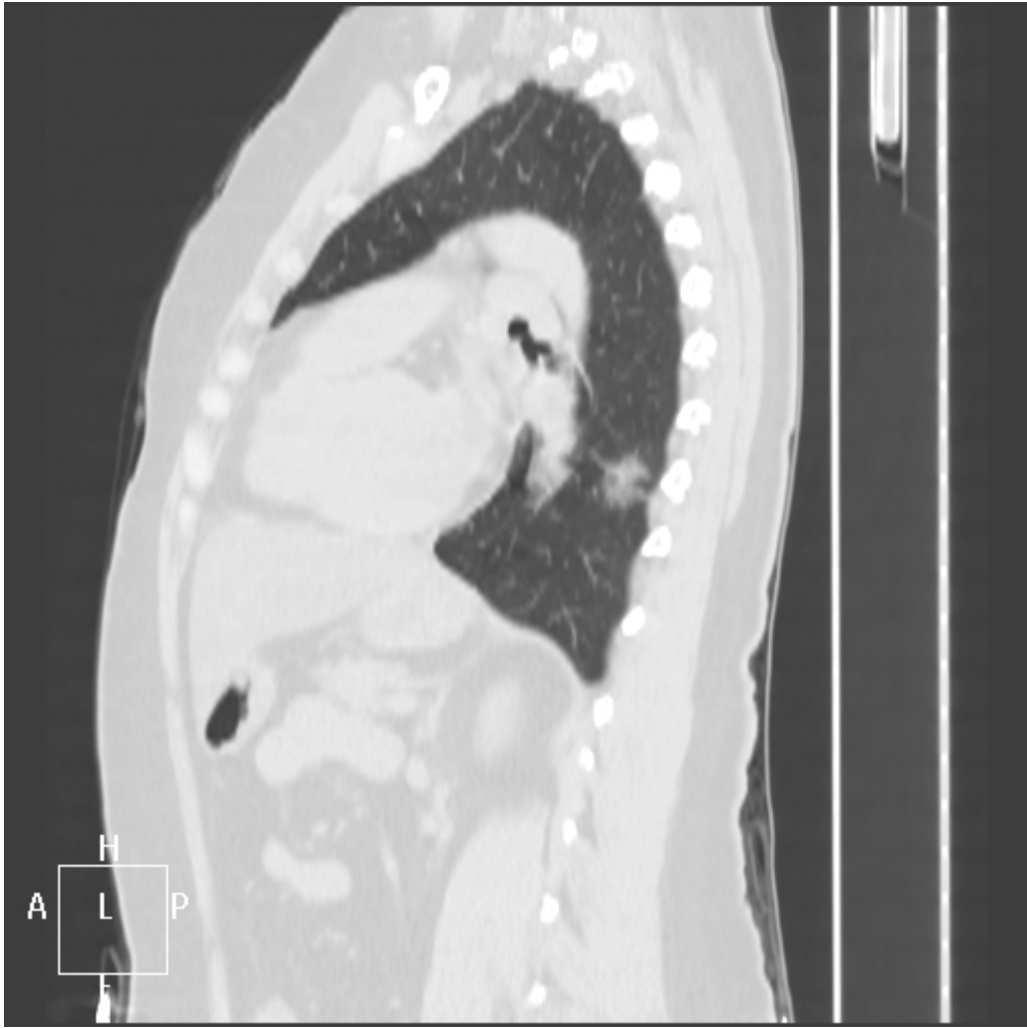
Chest radiography

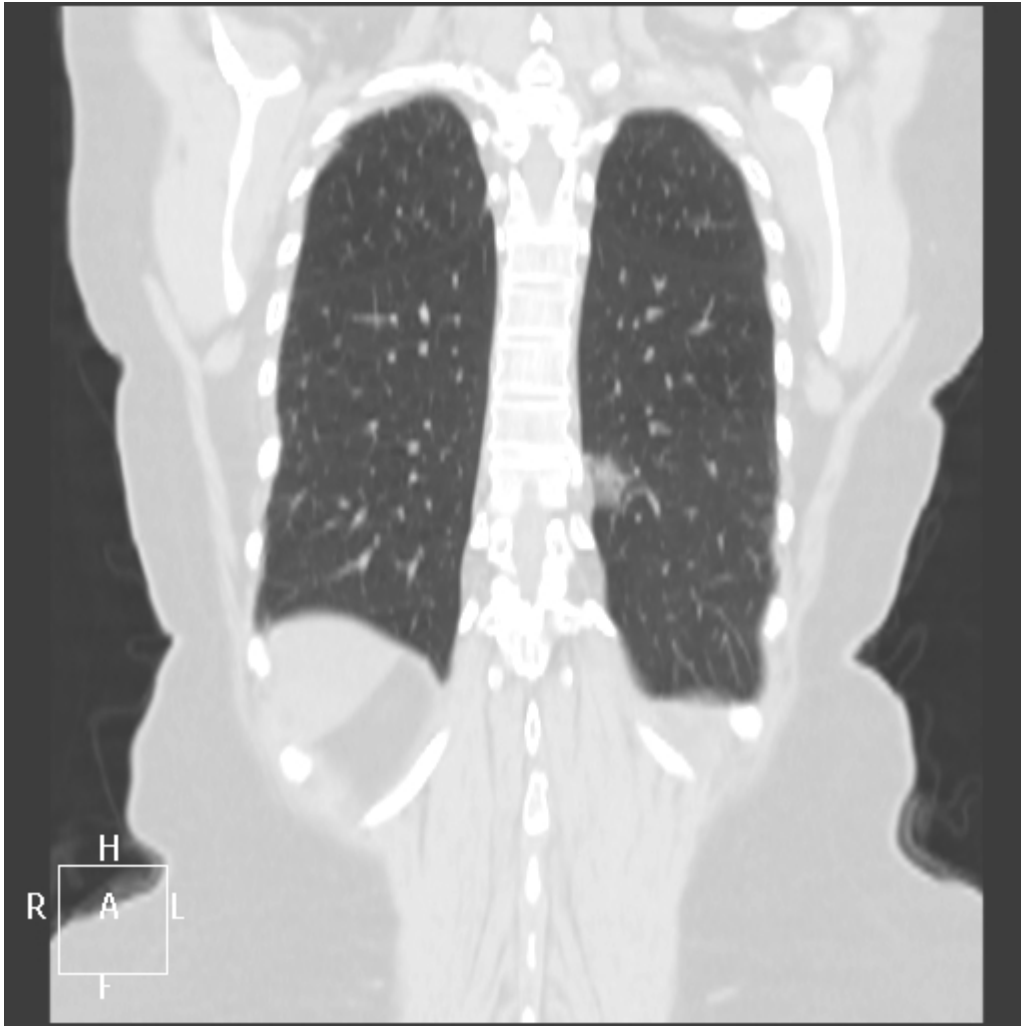


No pulmonary abnormalities.

CT







Subpleural ground-glass opacity in the left posterior basal segment, suspicious for early stage of Covid pneumonia. Fibrotic bands are also seen in the RLL.