

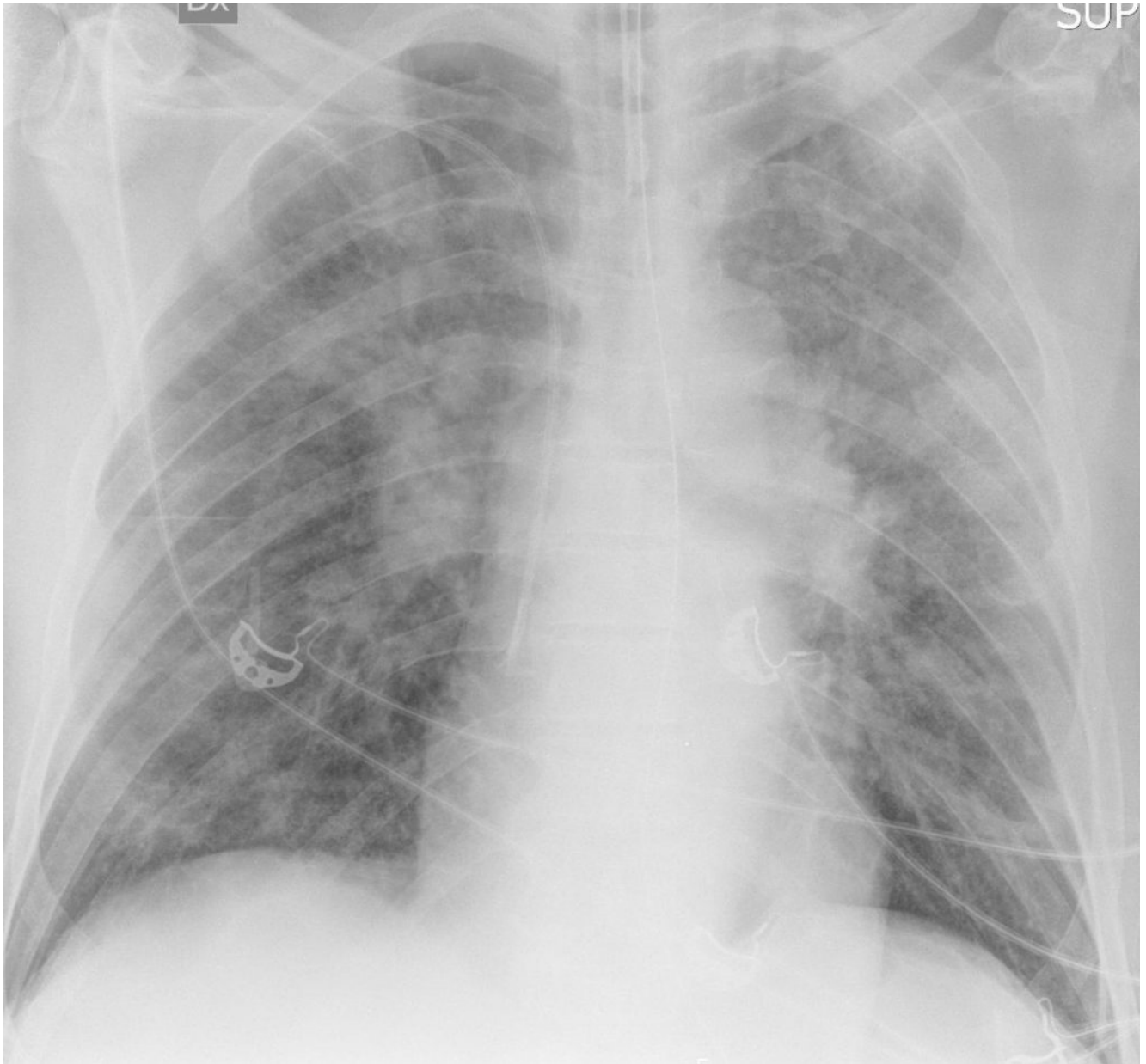
COVID-19: case 60

P. Nespoli, P. Moretto, D. Sardo, P. Hosseinollahi, A. De Pascale, G. Garofalo, A. Veltri

AOU San Luigi Gonzaga, Orbassano, Radiodiagnostica, Direttore:
Prof. A. Veltri

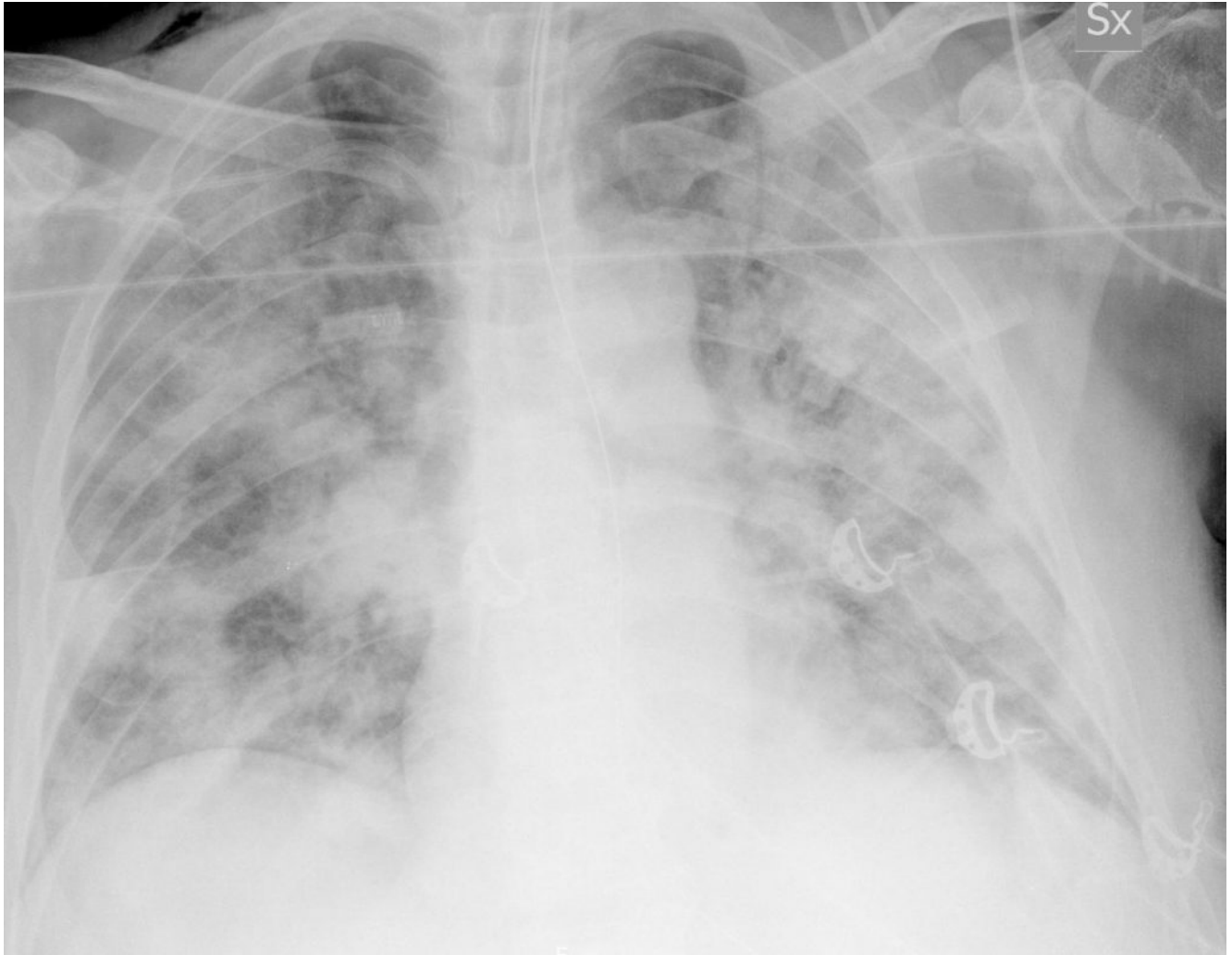
60-year-old male
patient with dyspnea and fever. No prior medical history.

Chest Radiography, March 6, 2020:



Bilateral pulmonary “ground-glass” opacities in the upper pulmonary lobes, findings consistent with pneumonia.

Chest Radiography, March 13, 2020:



Compared to the previous examination a radiological worsening is seen, with the onset of multiple and diffuse consolidations involving also the lower lobes. Findings consistent with multifocal pneumonia.