

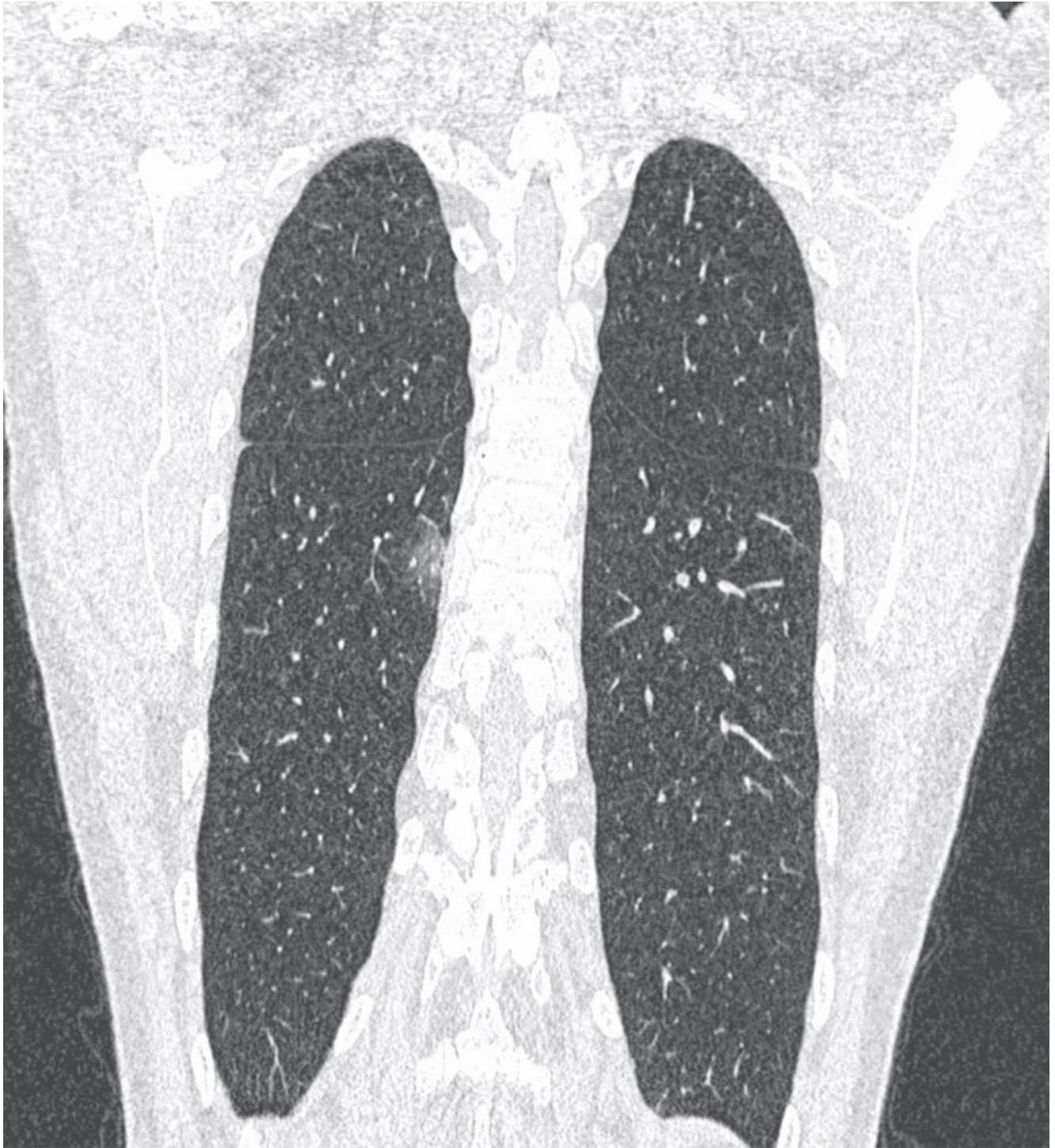COVID-19: case 62

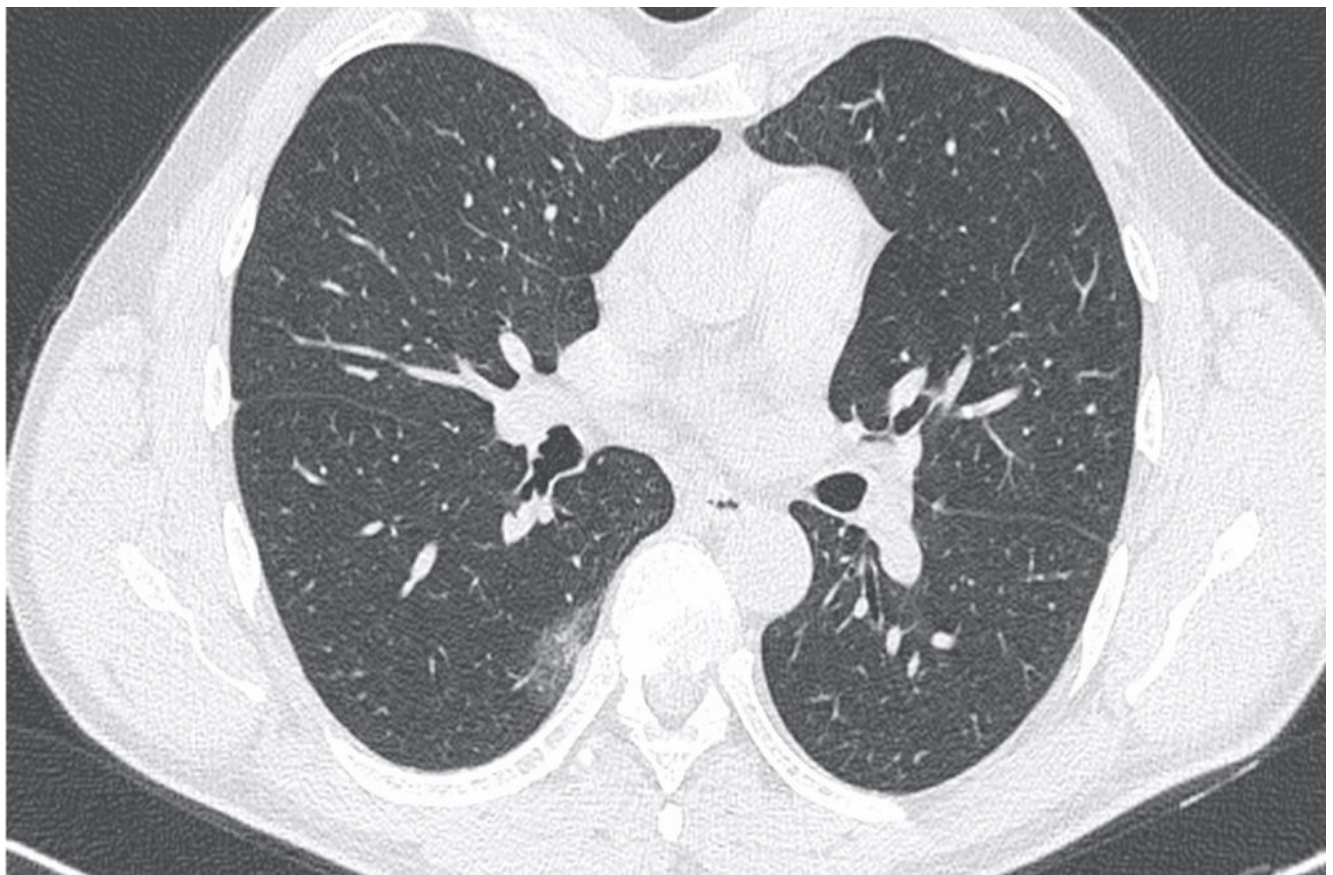
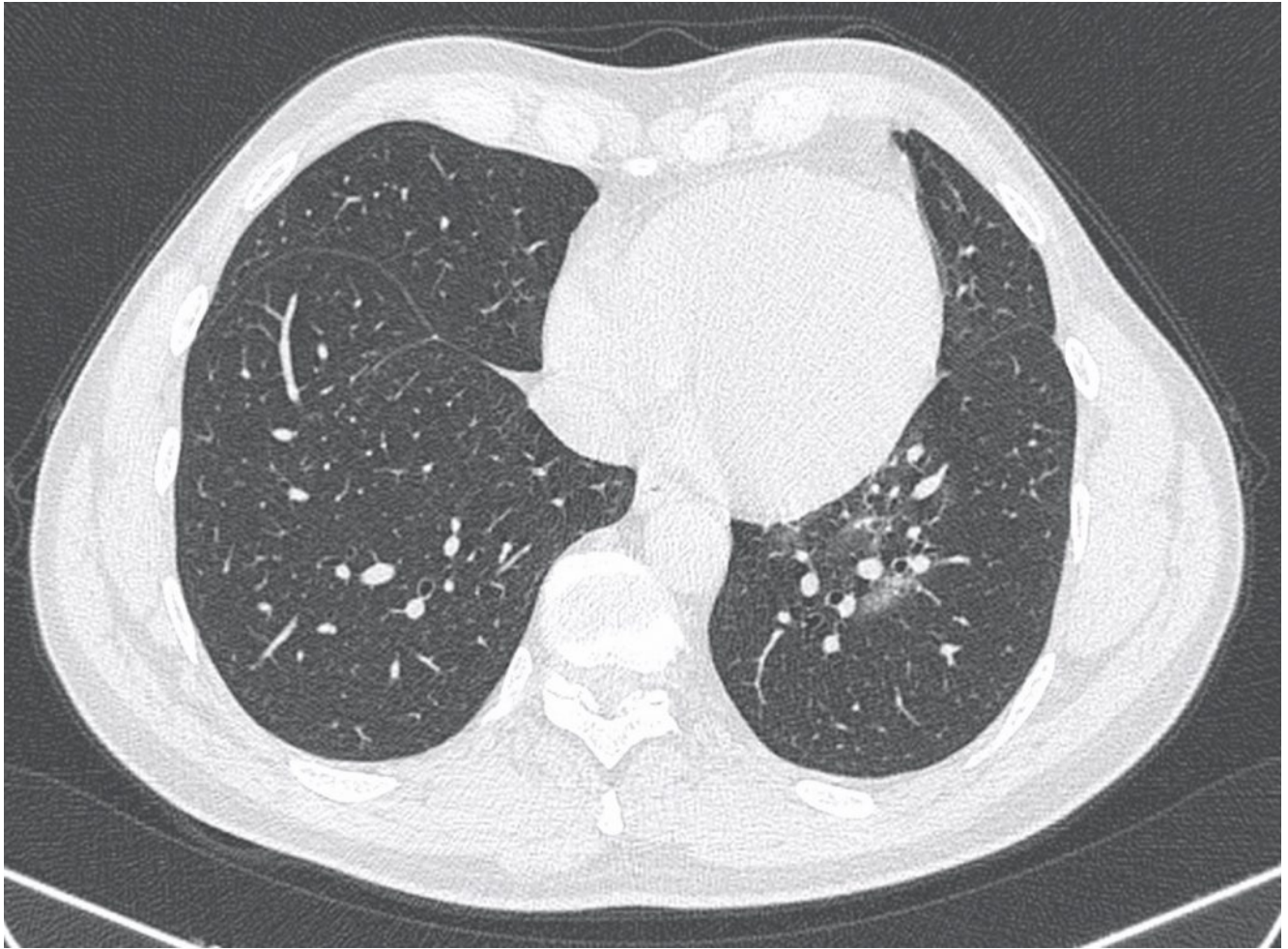Izzo Andrea, D'Aversa Lucia, Cerimoniale Giuseppe, Mazzella Giuseppe, Pergoli Pericle, Faiola Eugenio Leone, Casale Lorenzo, Di Pastena Francesca

U.O.C. Diagnostica per immagini – Ospedale “Dono Svizzero”
Formia DEA I livello– Asl Latina

56-year-old male patient presented to the ED with fever, anosmia, ageusia, pharyngalgia for 1 week. In self-isolation for Covid-19 positive contact. No prior medical history. Physical examination: no fever, pO₂ 97%.

CT





Ground-glass opacities with subpleural distribution in the apical and in the medial basal segments of the LLL, features consistent with interstitial pneumonia.