

COVID-19: case 63

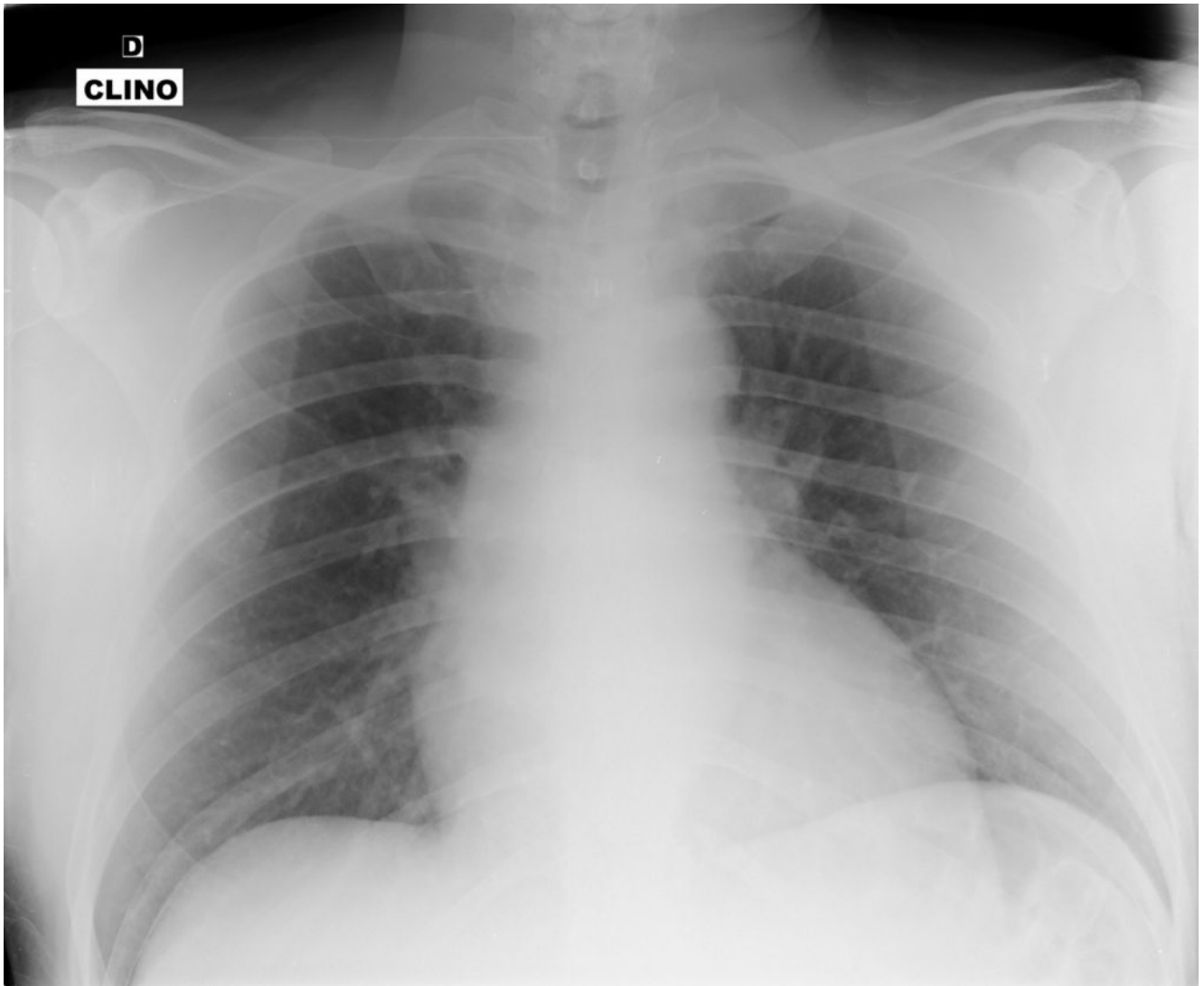
Izzo Andrea, D'Aversa Lucia, Cerimoniale Giuseppe, Mazzella Giuseppe, Pergoli Pericle, Faiola Eugenio Leone, Casale Lorenzo, Di Pastena Francesca

U.O.C. Diagnostica per immagini – Ospedale “Dono Svizzero”
Formia DEA I livello– Asl Latina

49-year-old male

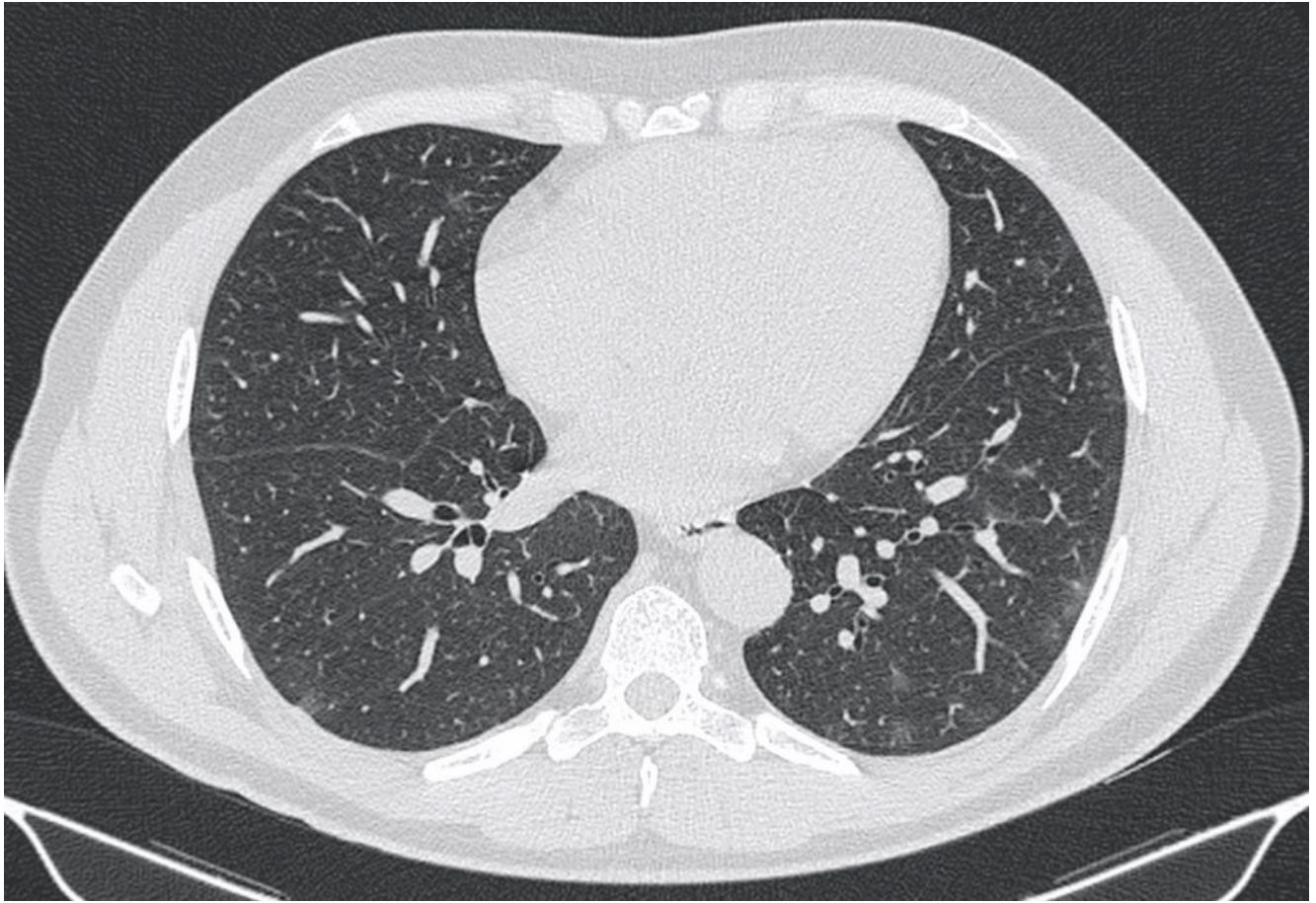
patient admitted to the ED with fever (39°C) and dyspnea for 4 days, in treatment with antibiotics for 2 days. No prior medical history

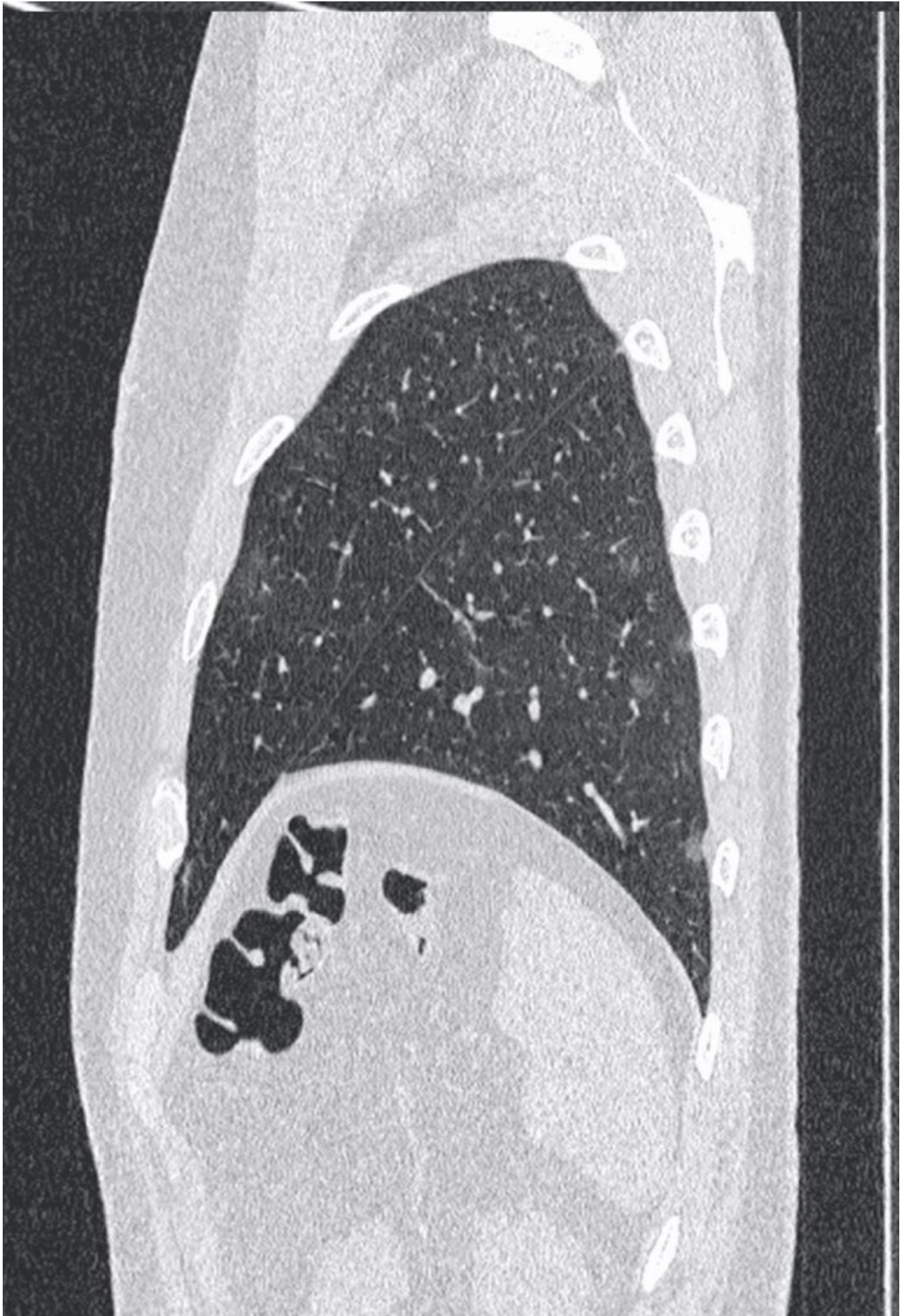Portable chest film (performed in a tent set up outside the ED):

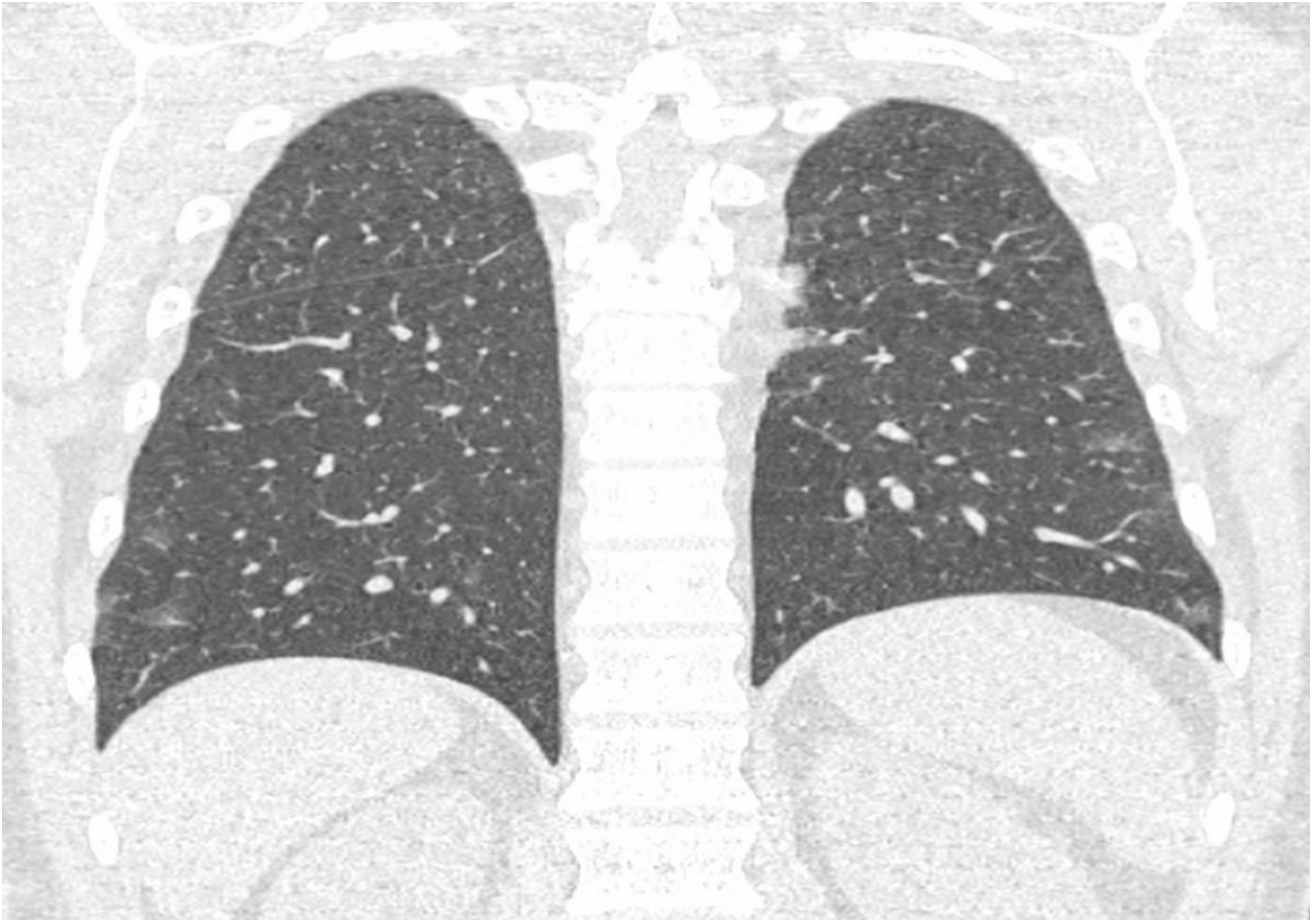


slight interstitial markings w/o alveolar consolidations.

CT







Multiple ground-glass opacities with predominant subpleural distribution in the RUL, in the ML and in the lower lobes. The findings were consistent with Covid-19 pneumonia.

The RT-PCR test on nasopharyngeal swab turned positive.