

COVID-19: case 64

Izzo Andrea, D'Aversa Lucia, Cerimoniale Giuseppe, Mazzella Giuseppe, Pergoli Pericle, Faiola Eugenio Leone, Casale Lorenzo, Di Pastena Francesca

U.O.C. Diagnostica per immagini – Ospedale “Dono Svizzero”
Formia DEA I livello– Asl Latina

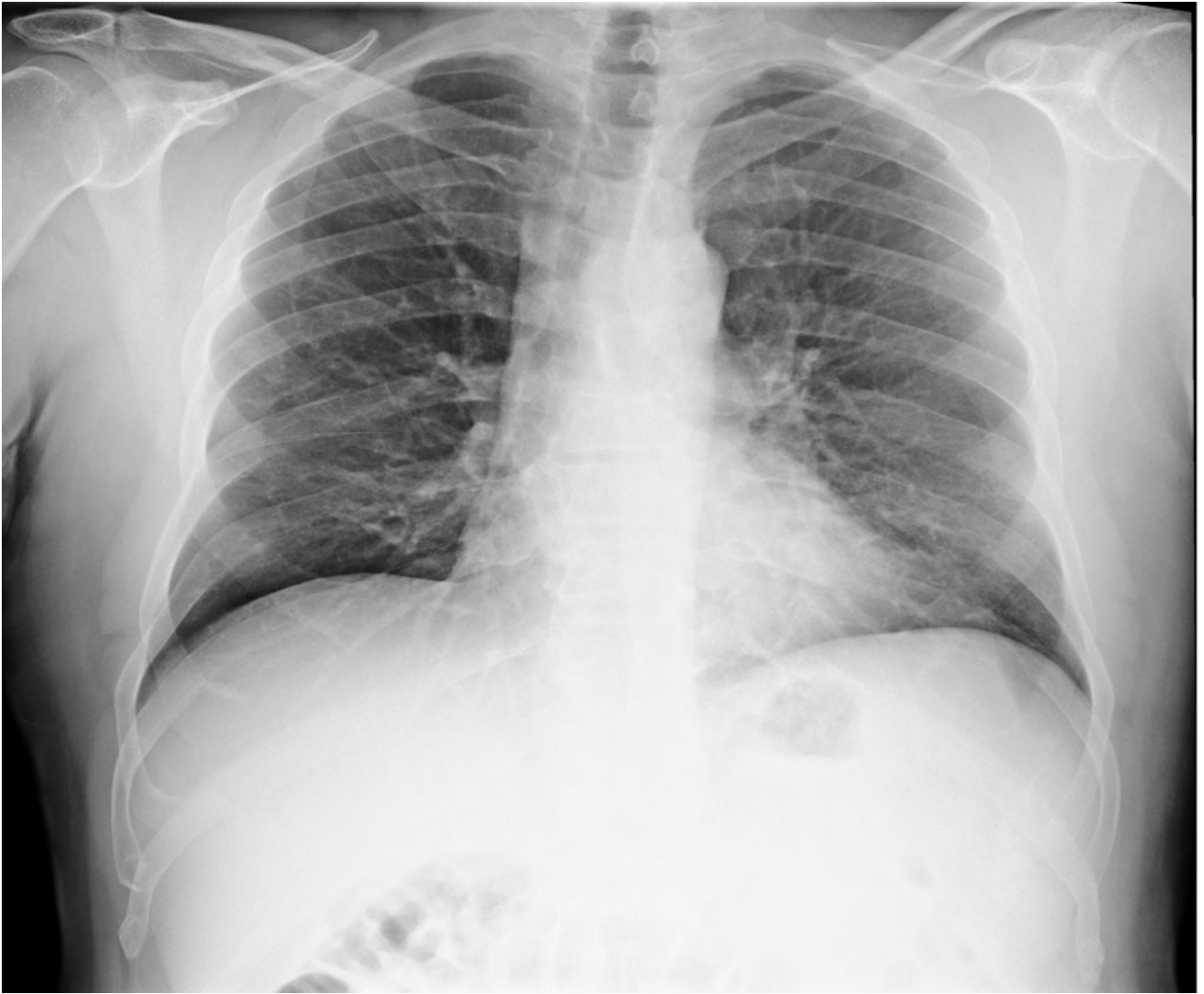57-year-old male

patient admitted to the ED with fever, cough and dyspnea for 3 days. No prior medical history. No epidemiologic risk for SARS-CoV-2 exposure.

Medical

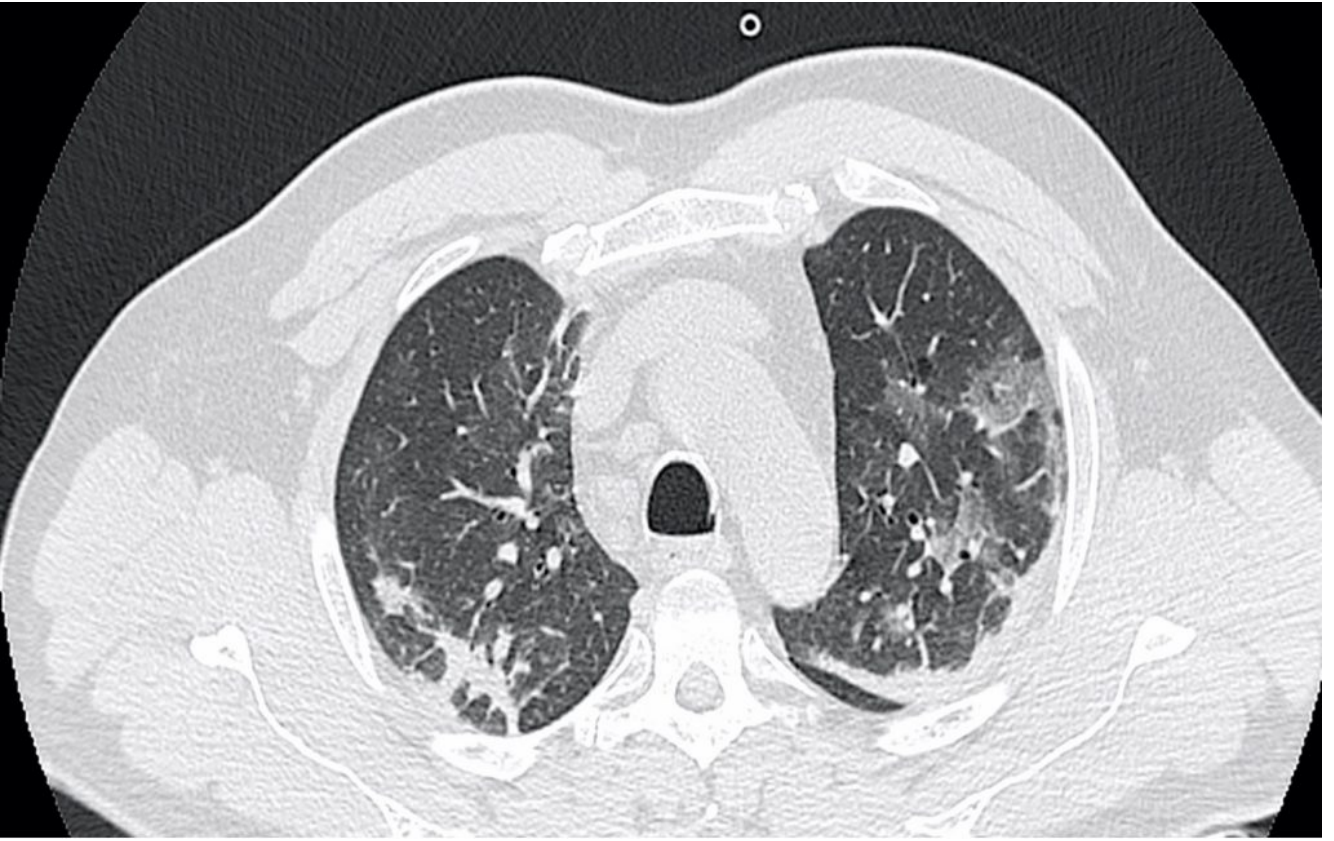
examination: dyspnea, tachypnea, fever (39°C). pO₂ 90%.

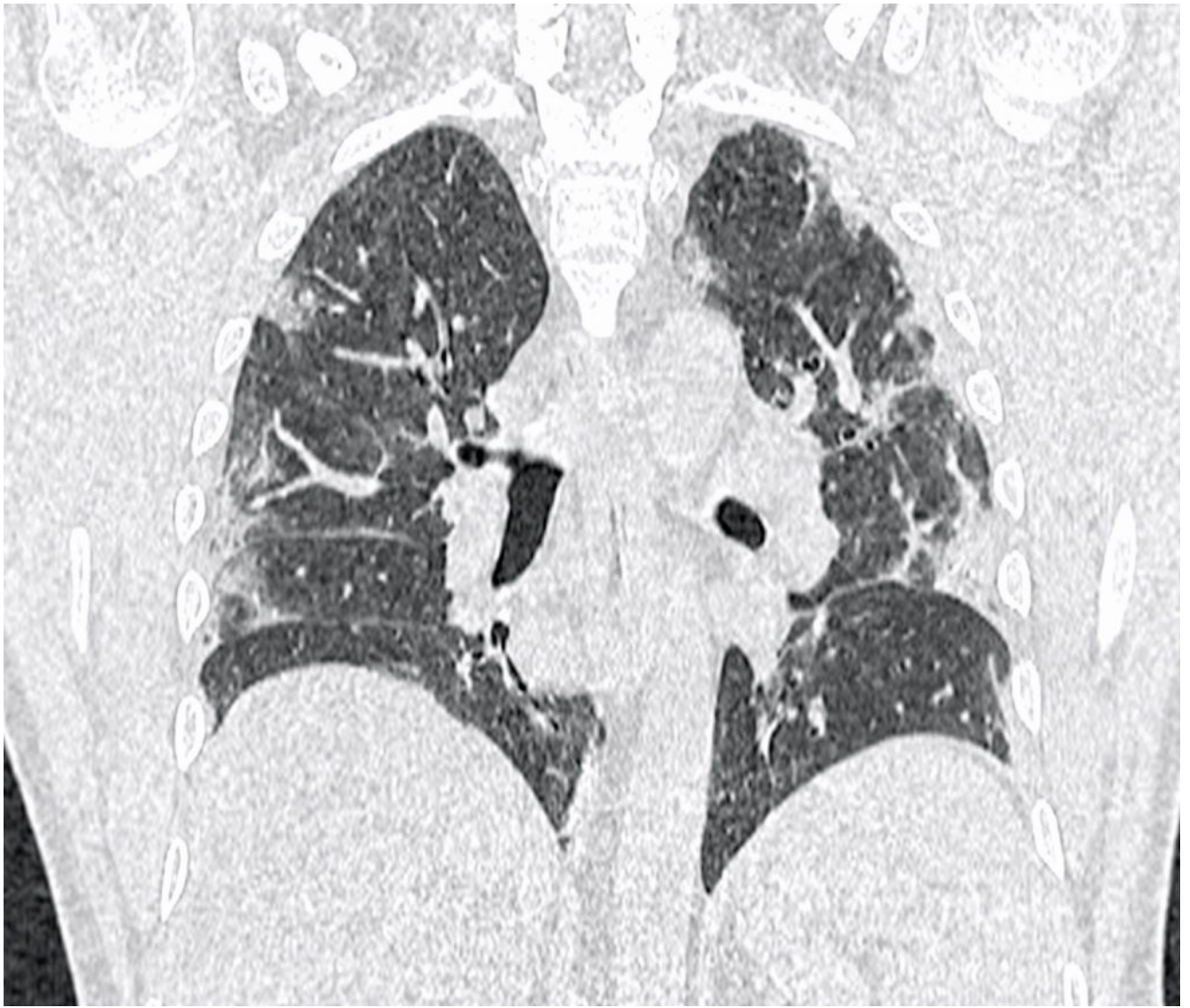Chest radiography:

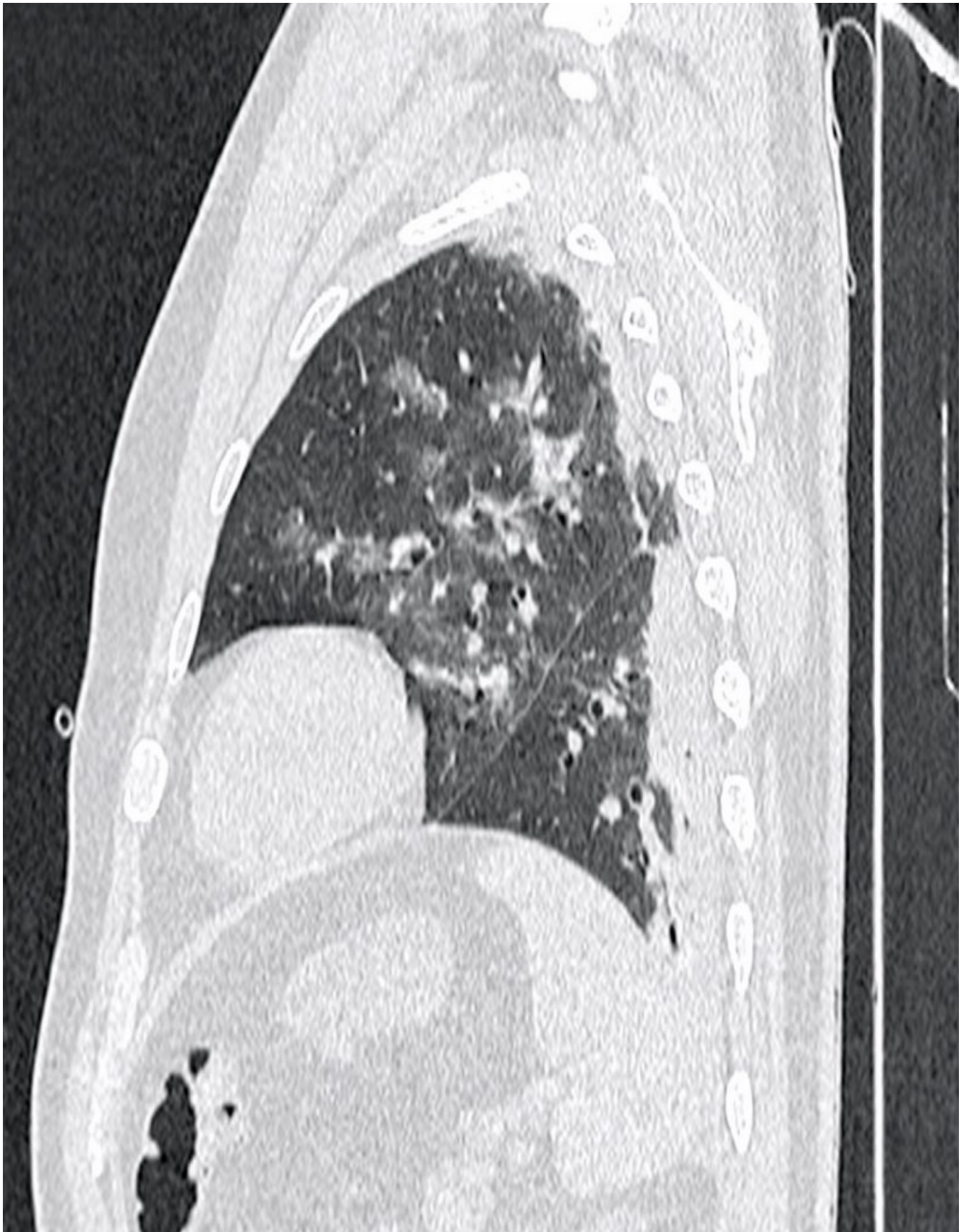


Interstitial markings with opacities at the left base.

CT







Multiple ground-glass opacities associated with scattered areas of GGOs and reticulations

in a “crazy-paving pattern” and consolidations.

Features were consistent
with Covid-19 pneumonia.

RT-PCR on nasopharyngeal swab was positive.