

# COVID-19: case 65

Izzo Andrea, D'Aversa Lucia, Cerimoniale Giuseppe, Mazzella Giuseppe, Pergoli Pericle, Faiola Eugenio Leone, Casale Lorenzo, Di Pastena Francesca

U.O.C. Diagnostica per immagini – Ospedale “Dono Svizzero”  
Formia DEA I livello– Asl Latina

74-year-old male

patient presented to the ED with chest pain and vomiting for 12 hours. Medical

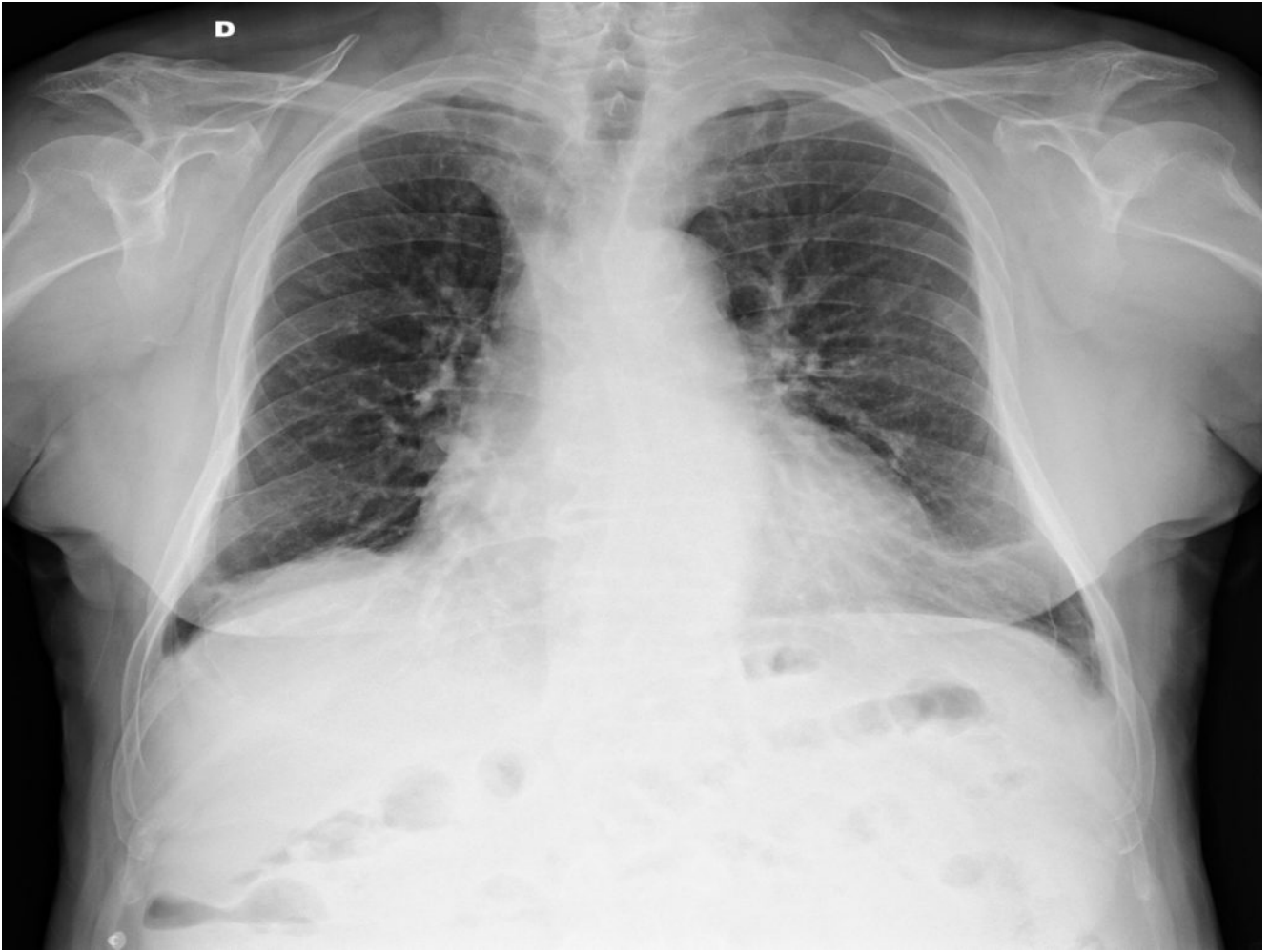
history: chronic myocardial ischemia, asthma; in treatment with oral

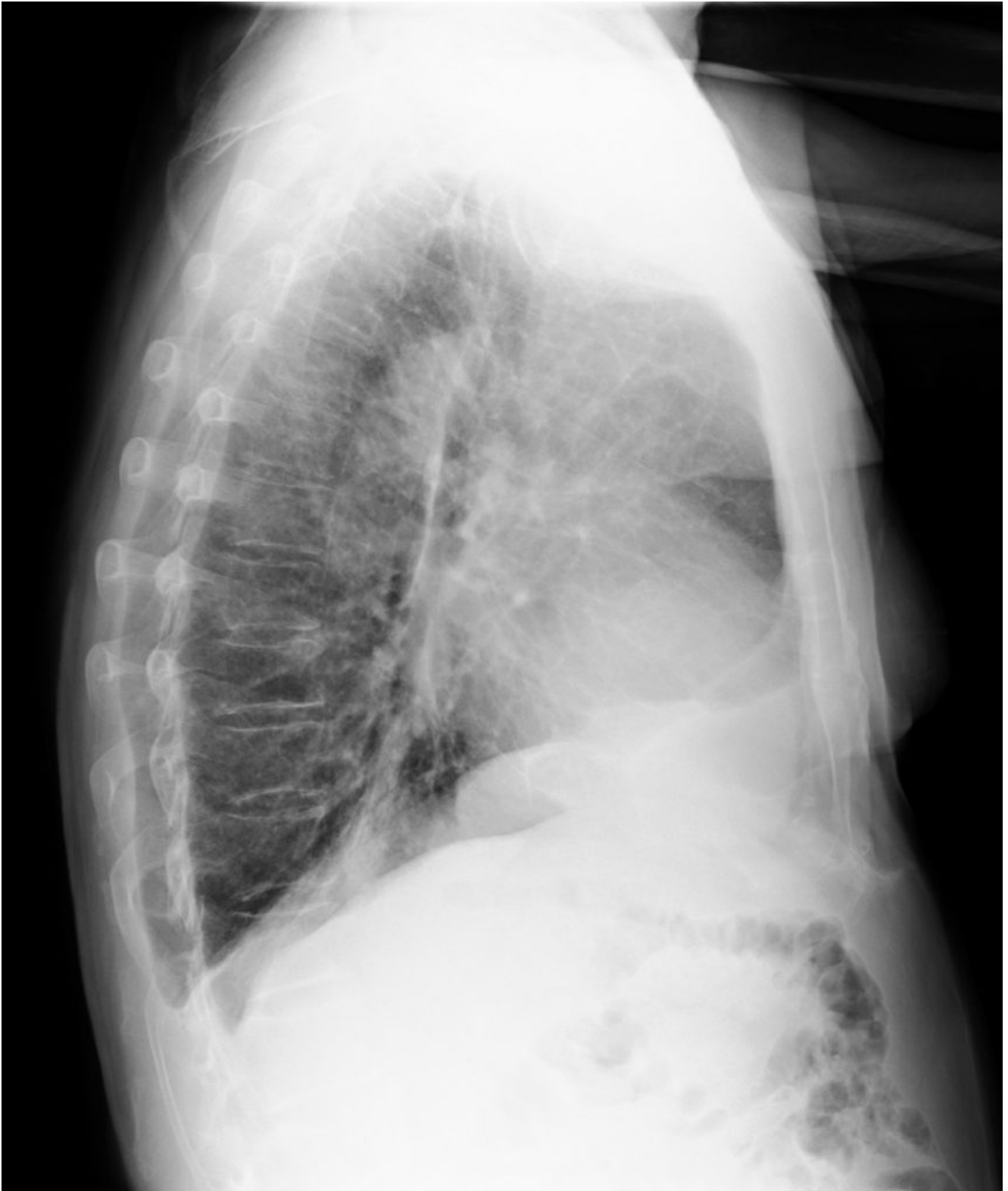anticoagulants. Epidemiologic risk for SARS-CoV-2 exposure.

Medical

examination: dyspnea, tachypnea, no fever. pO<sub>2</sub> 94%.

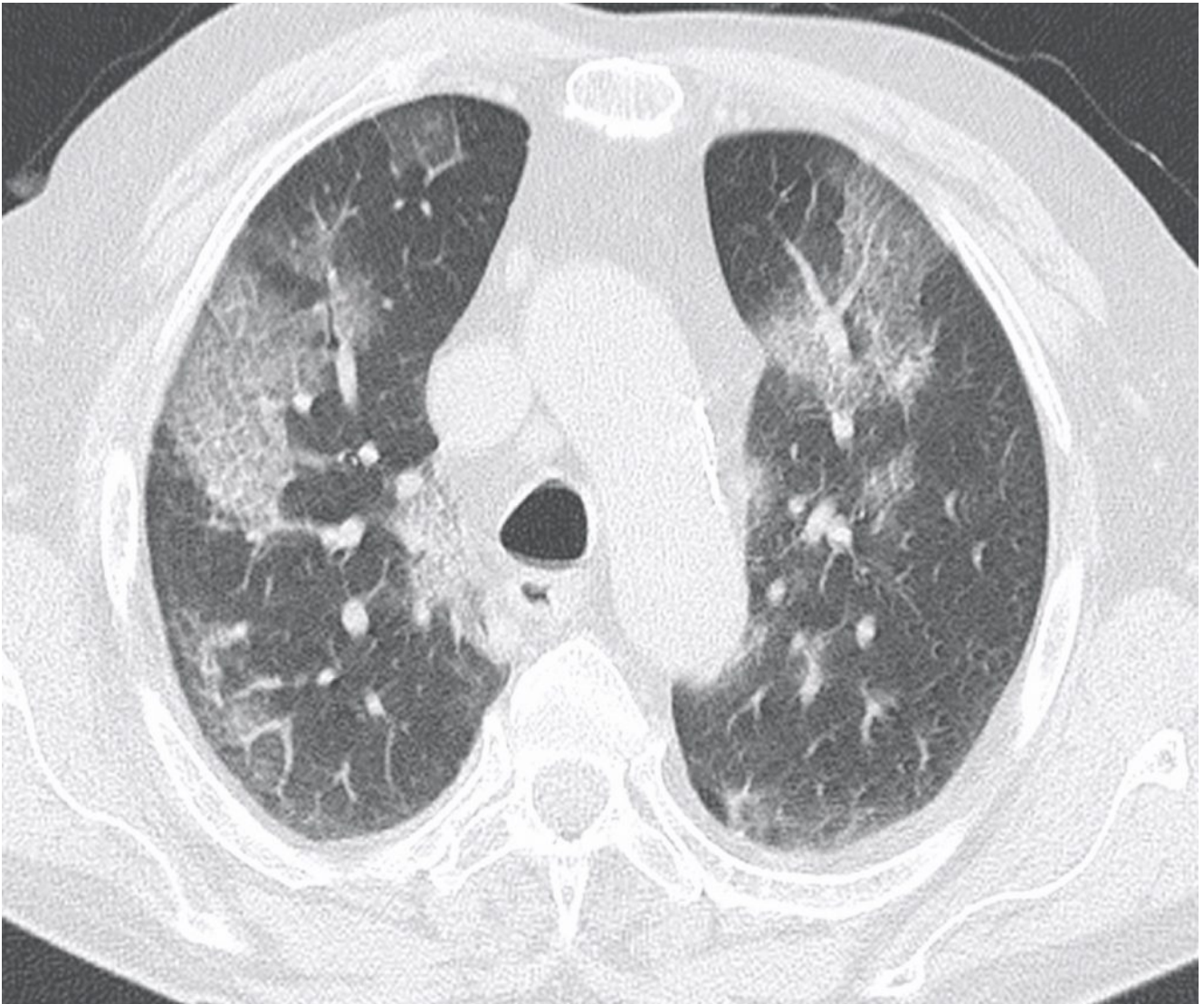
Chest radiography:

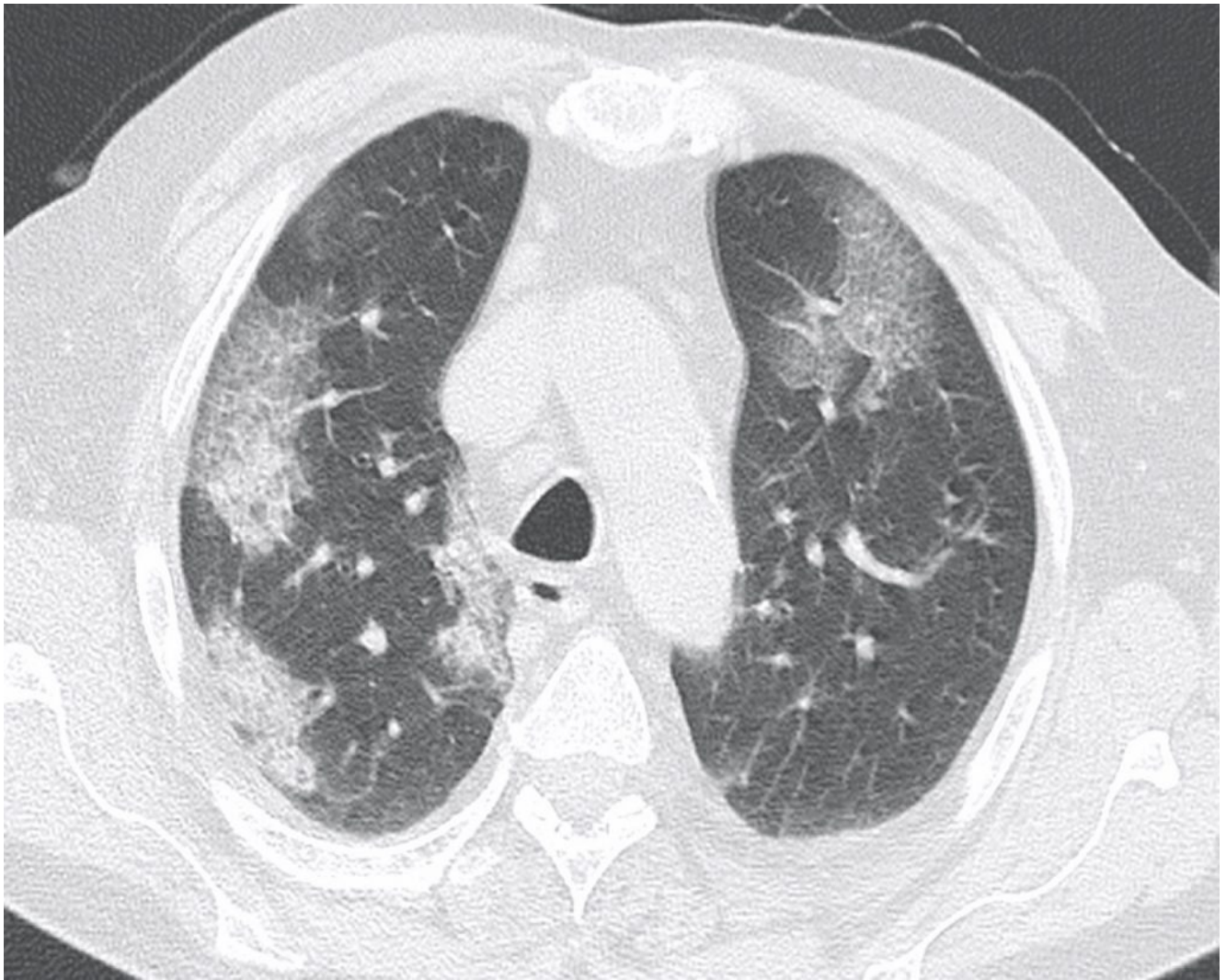


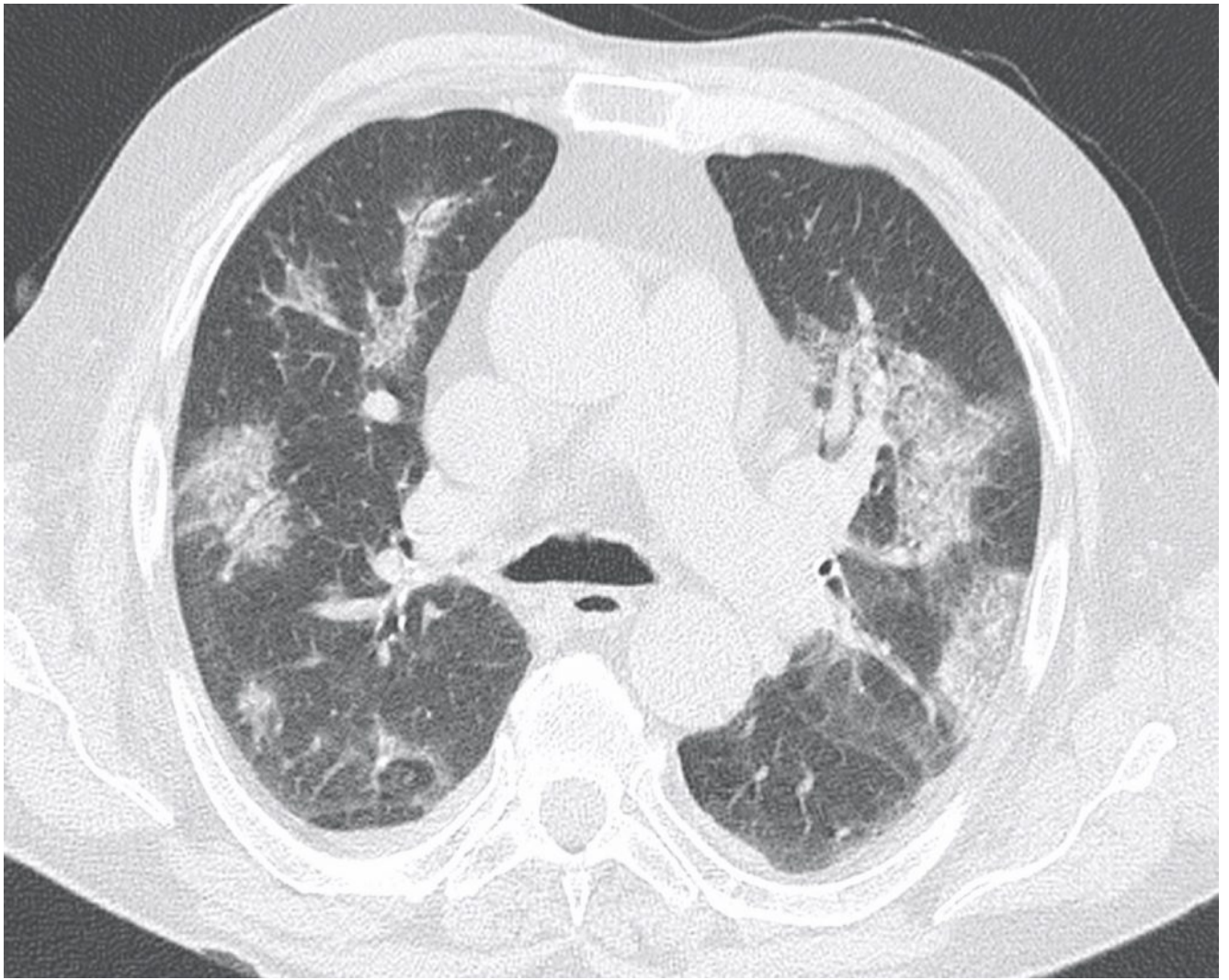


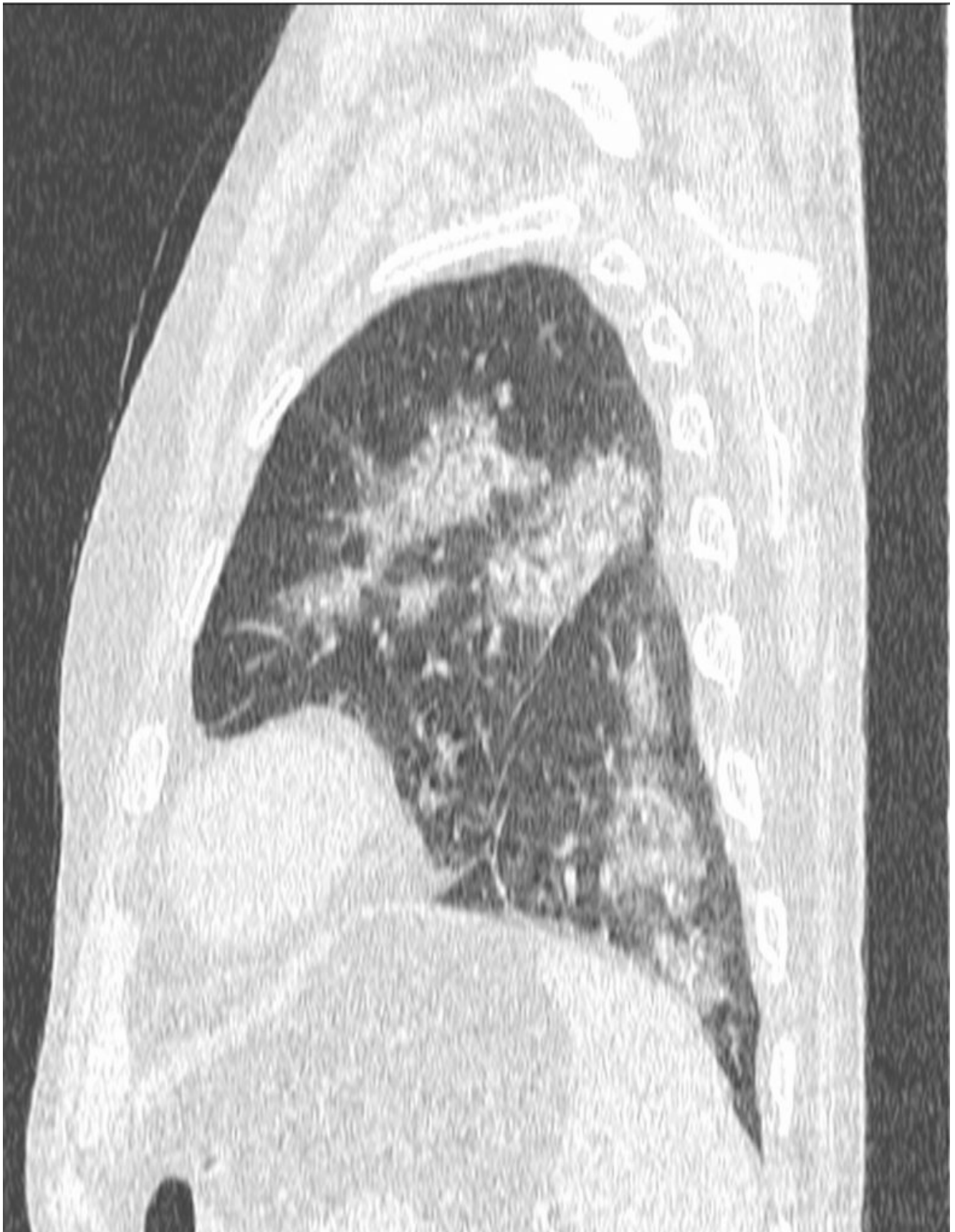Interstitial markings with consolidation at the right basis and opacities in the upper and medium lung regions.

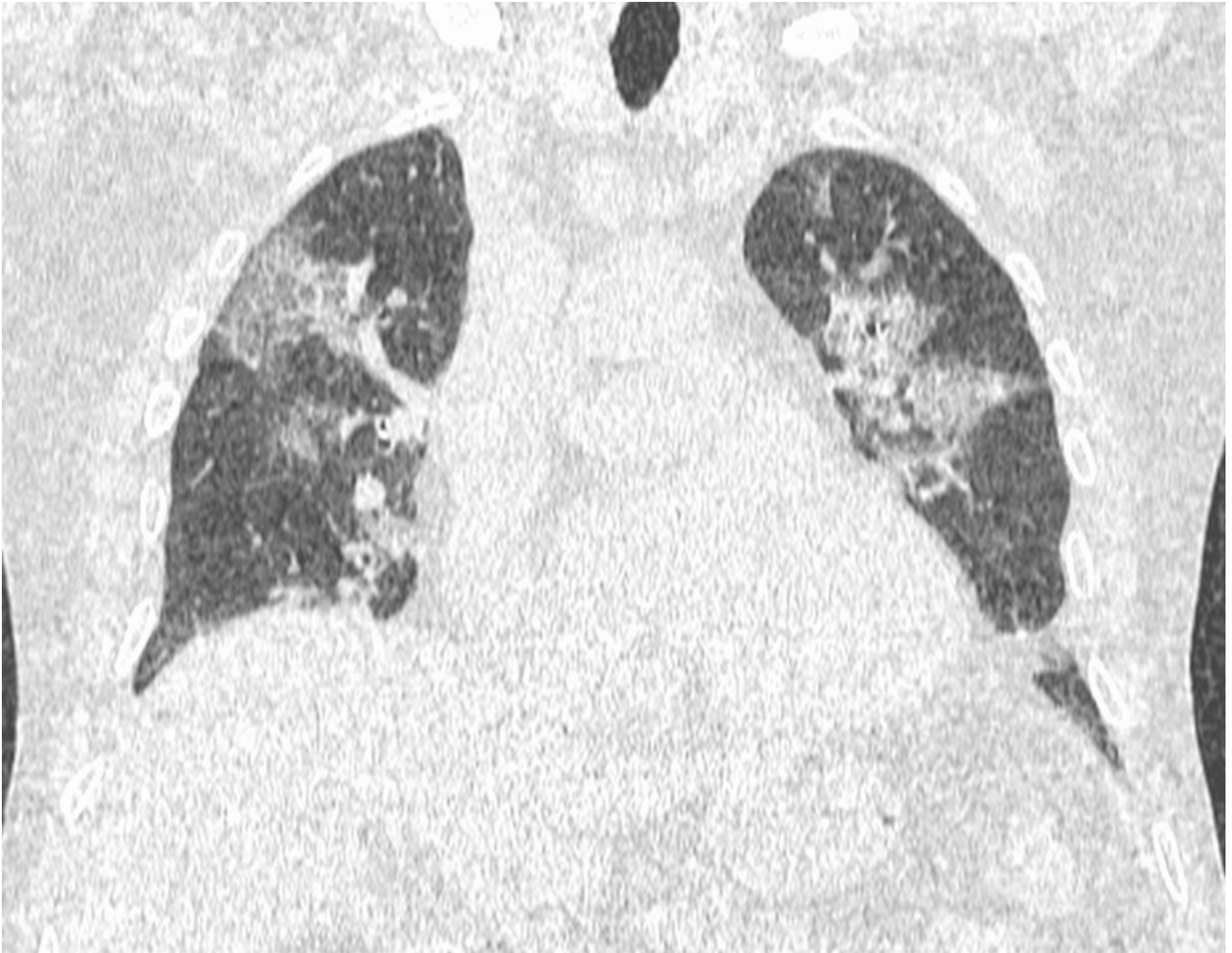Because of the epidemiologic risk and chest findings, a CT is performed.











Multiple ground-glass opacities associated with areas of GGOs and reticulations in a "crazy-paving pattern". Consolidation at the right posterior base. Fibrotic bands at the left posterior base. Features consistent with Covid-19 pneumonia. RT-PCR test on nasopharyngeal swab was positive.