

# COVID-19: case 68

Marta Brandani, Medico Radiologo, Ospedale Santa Maria alla  
Gruccia (Valdarno, Provincia di Arezzo)

77-years-old male admitted to ED for diarrhea, vomit and  
epigastralgia for 15 days.

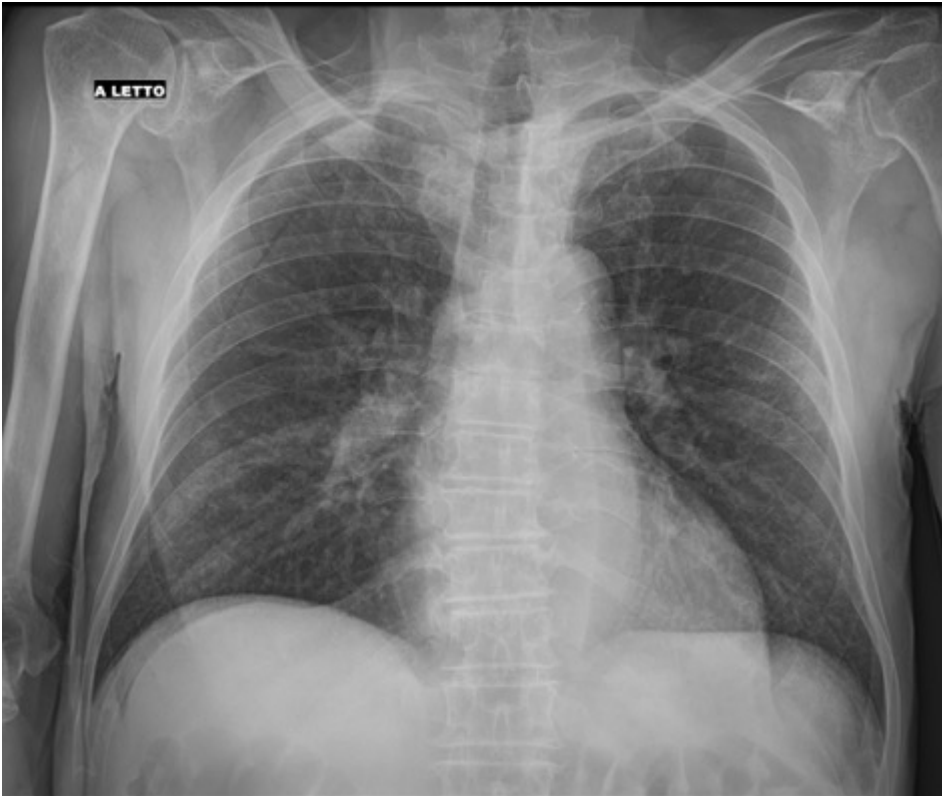
Exposure to Covid-19 patient.

Medical history: HTA, polymyalgia rheumatica, Horton's  
arteritis, ex-smoker.

Slight increase of LDH and CPR, lymphopenia.

Chest sonography: unremarkable

Chest radiography



The next morning: fever 39 C°, pO<sub>2</sub> 96% con O<sub>2</sub> 3 l/min. In the afternoon: EGA in O<sub>2</sub> 3l/min (PH 7.49, pO<sub>2</sub> 80.3, pCO<sub>2</sub> 31, satO<sub>2</sub> 95%, HC0<sub>3</sub> 24). Next check with ventimask 40%: PH 7.47, pO<sub>2</sub> 109, pCO<sub>2</sub> 35, satO<sub>2</sub> 97%, HC0<sub>3</sub> 25.

Chest sonography: bilateral interstitial disease with consolidations.

RT-PCR positive for SARS-CoV-2.