

# COVID-19: case 3

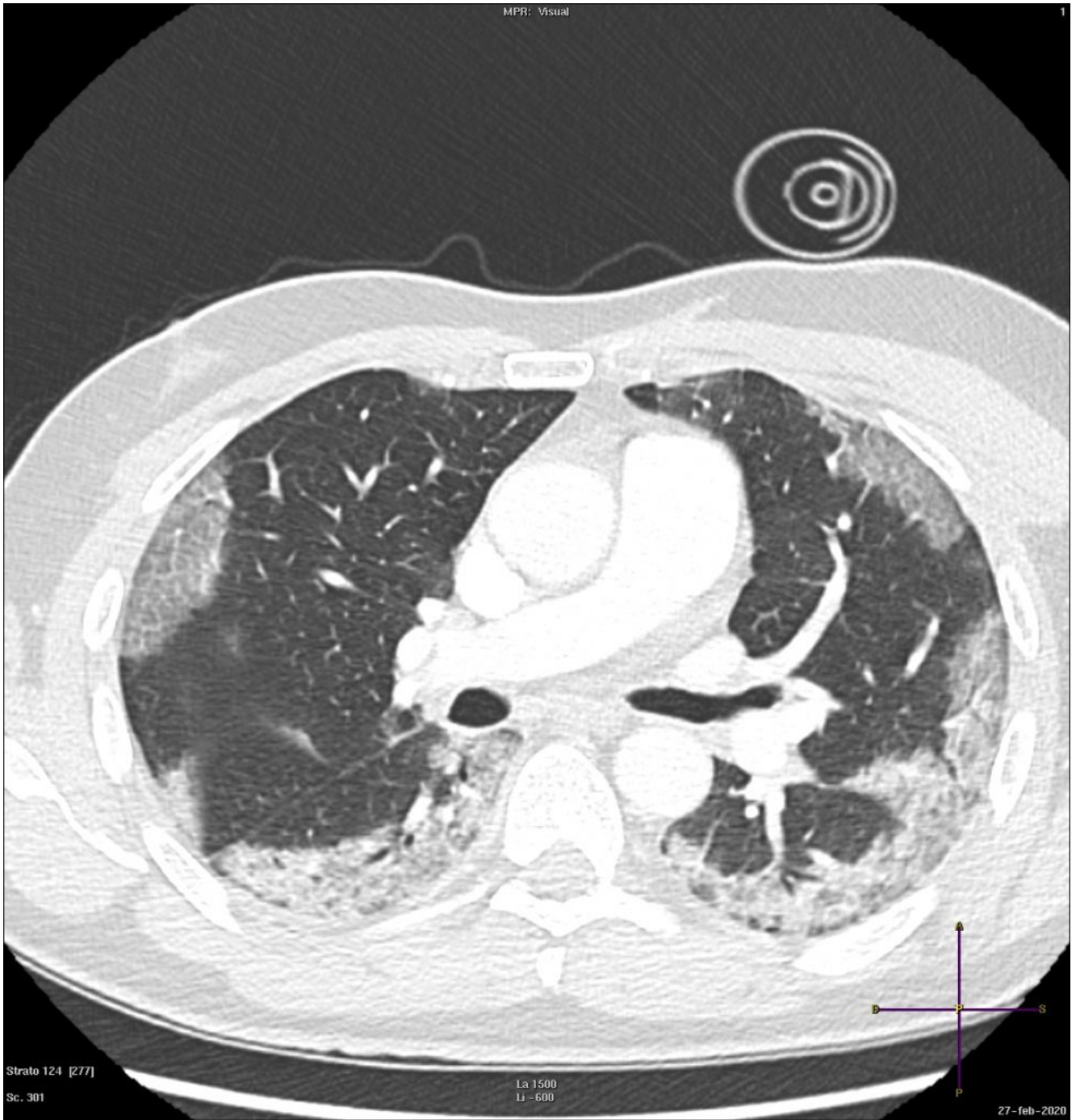
Radiologia ASST Cremona

57-year-old male patient with fever, cough. No previous medical history. Potential exposure to Covid-19 patients.

Respiratory

failure (hypoxemia and hypocapnia). Leukocitosi. Nasal swab positive for SARS-CoV-2.

HRCT

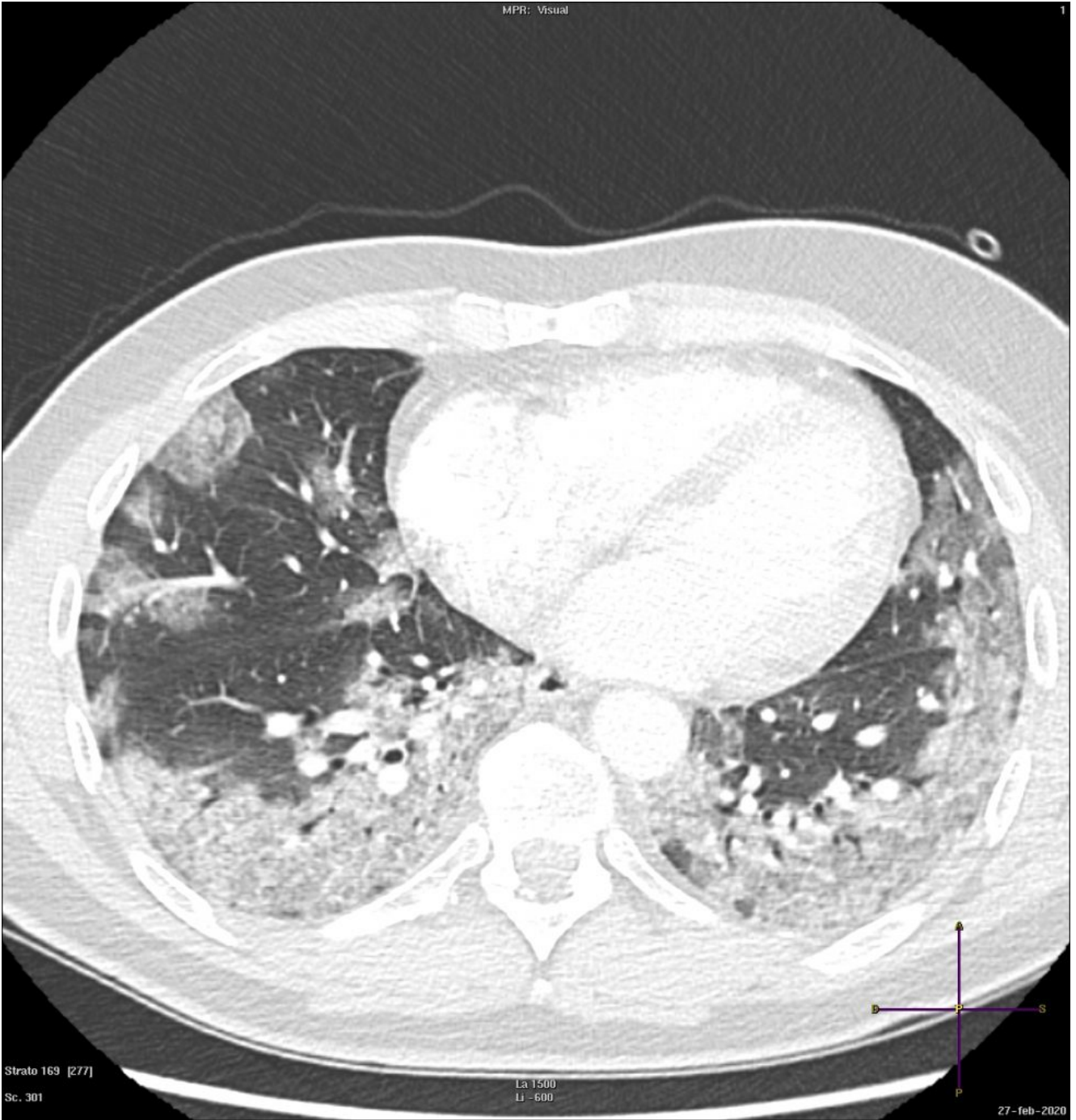


Strato 124 [277]

Sc. 301

La 1500  
Li -600

27-feb-2020

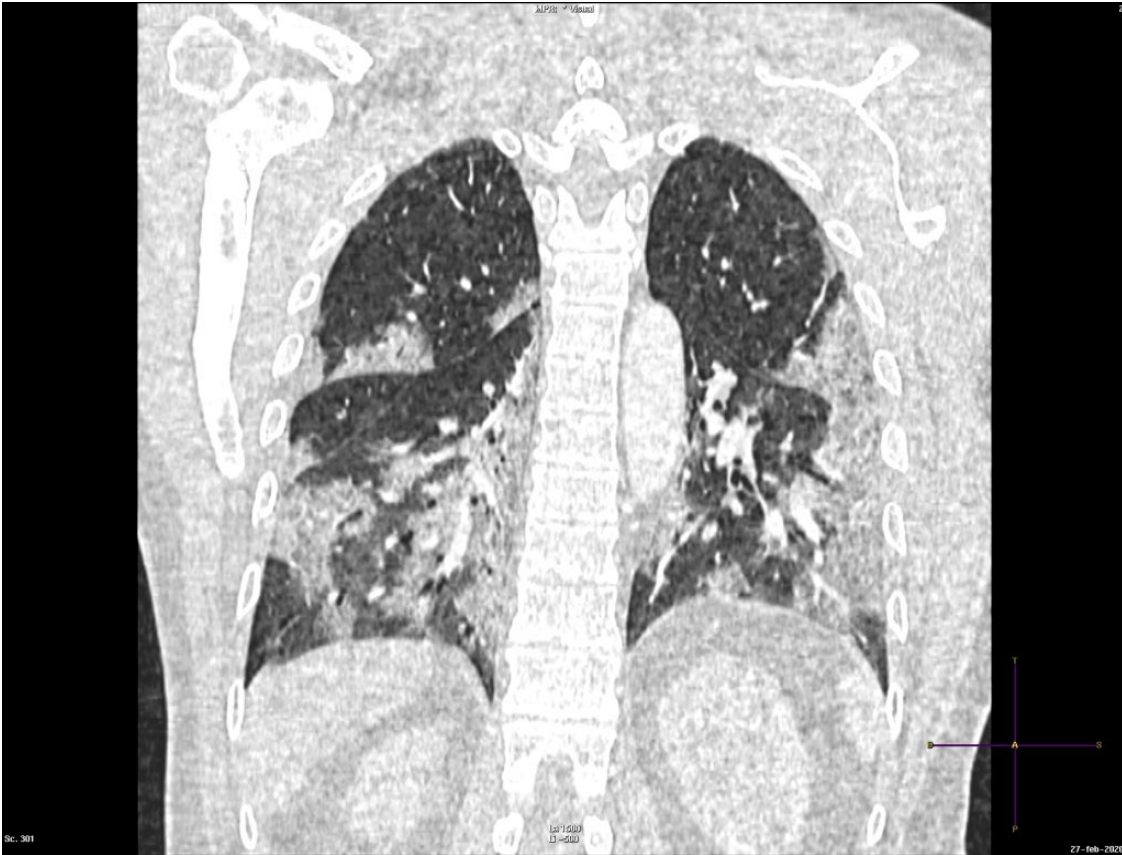

Strato 169 [277]

Sc. 301

La 1500  
Li -600

27-feb-2020



Subpleural ground-glass opacity with predominant subpleural distribution and consolidations in all lobes, particularly in the lower lobes.

---

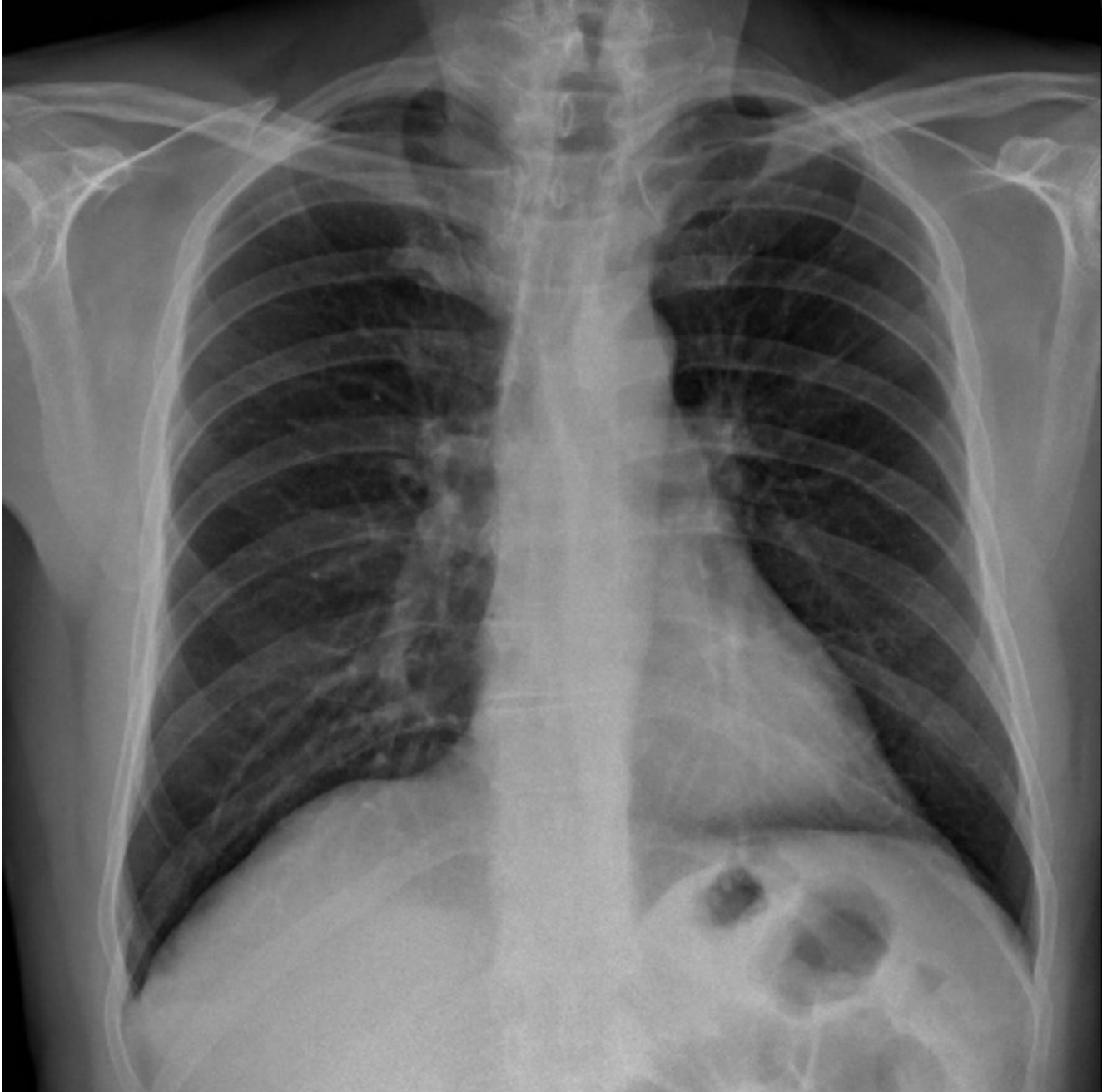## **COVID-19: case 2**

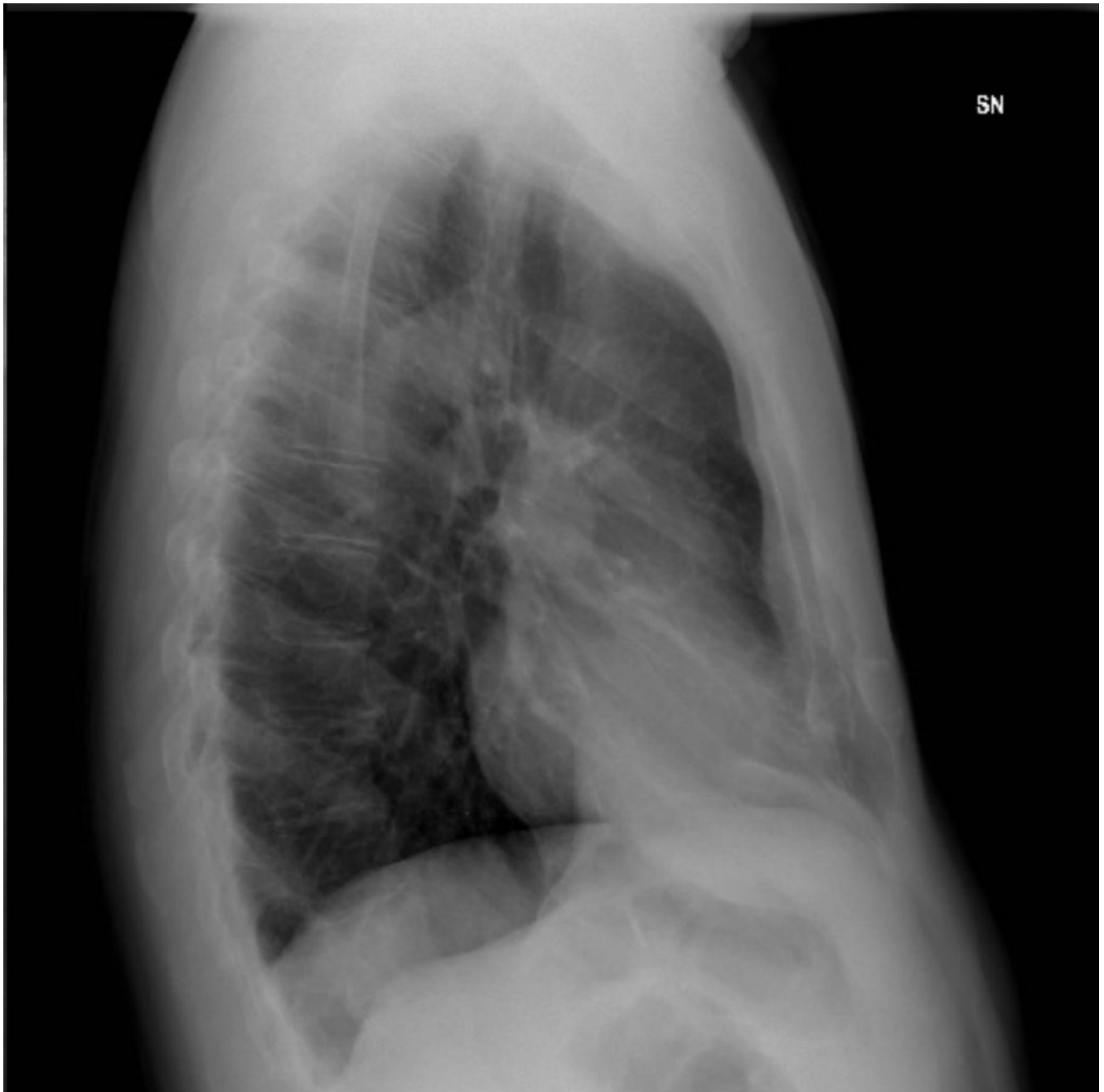
G.Patelli, F.Besana, S. Paganoni, A. Lenzi, F. Codazzi, L.Di Mare, G.Esposito, C. Sala

UOC Radiologia ASST Bergamo Est Direttore Dr Gianluigi Patelli

62-year-old male patient with fever, cough and asthenia for three days. No previous medical history. pO<sub>2</sub> 97%, C.RP 0.75.

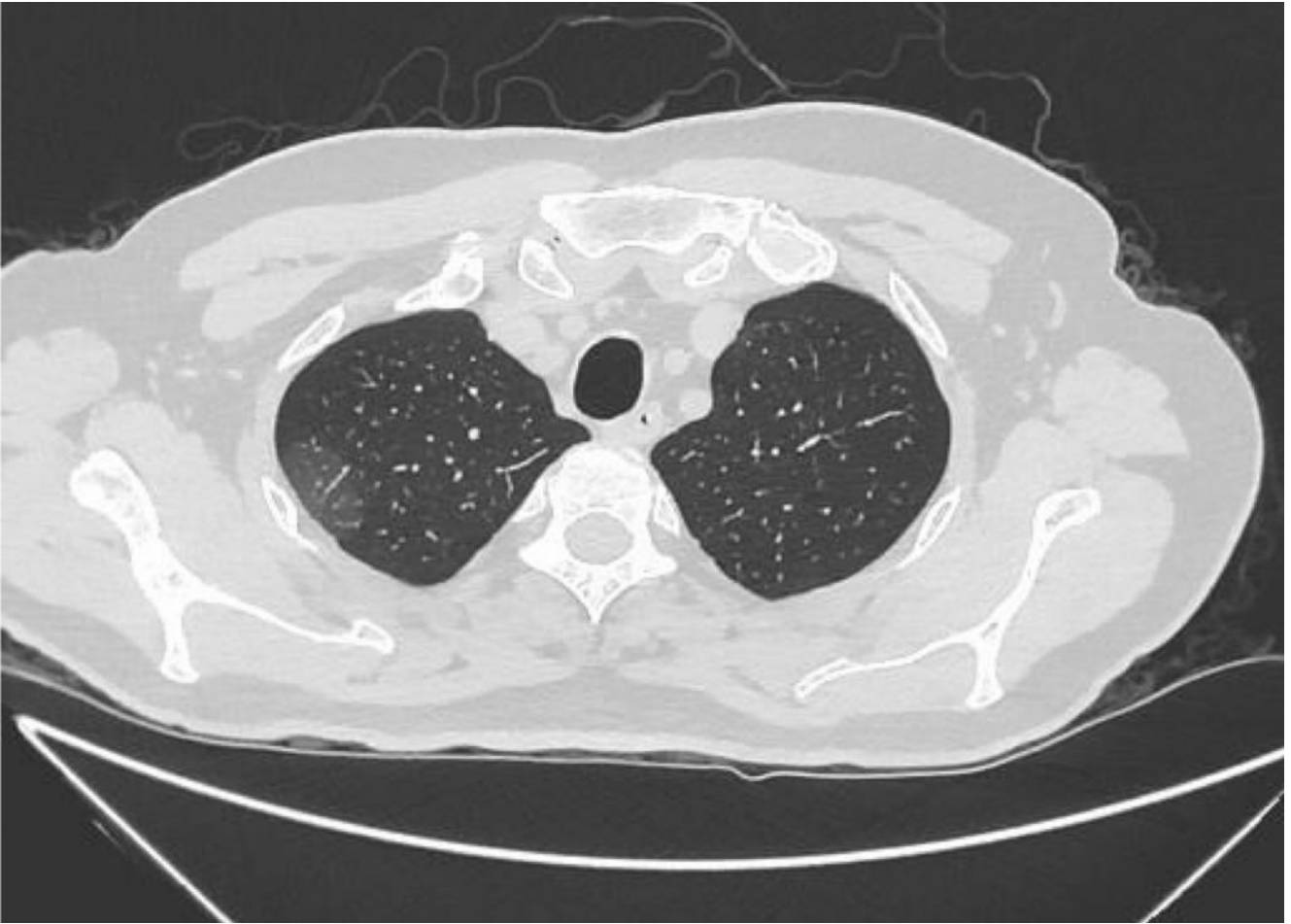
Chest radiography:

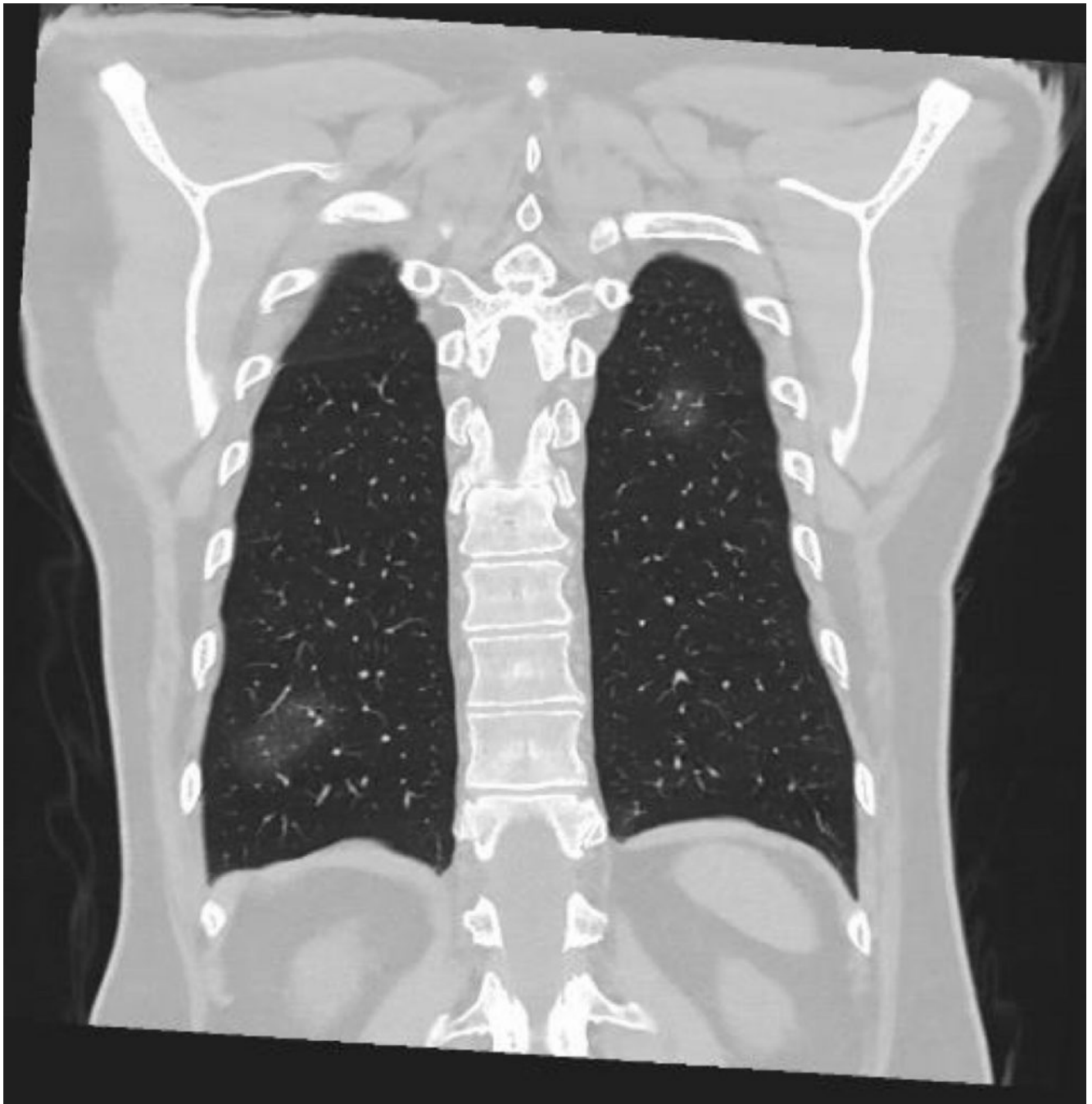




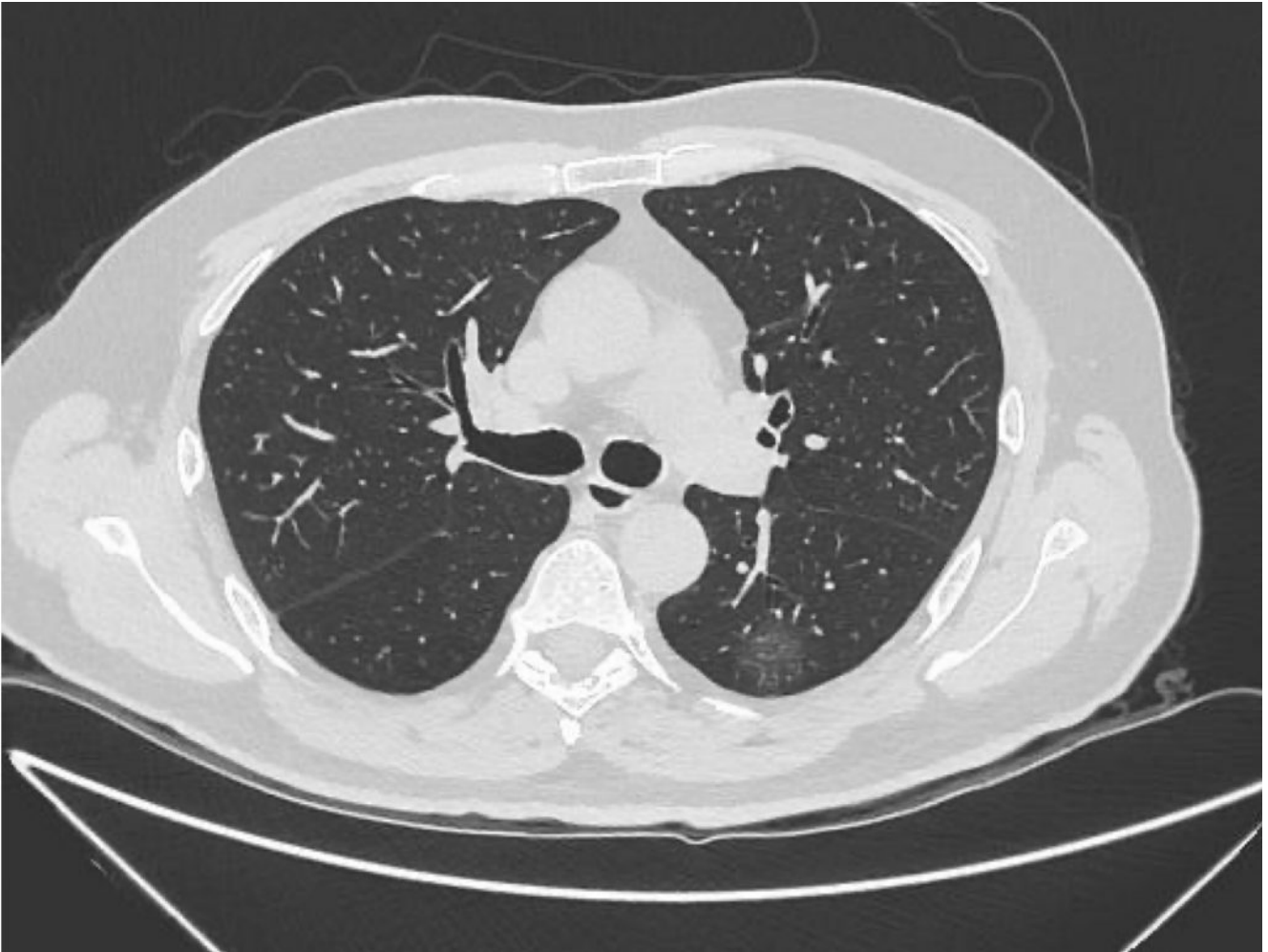
negative.

Due to the discrepancy between CXR and the clinical examination a CT is performed.









Scattered blurred ground-glass opacities suspected for early stage on interstitial pneumonia.

Nasal swab positive for SARS-CoV-2.

---

## **COVID-19: case 1**

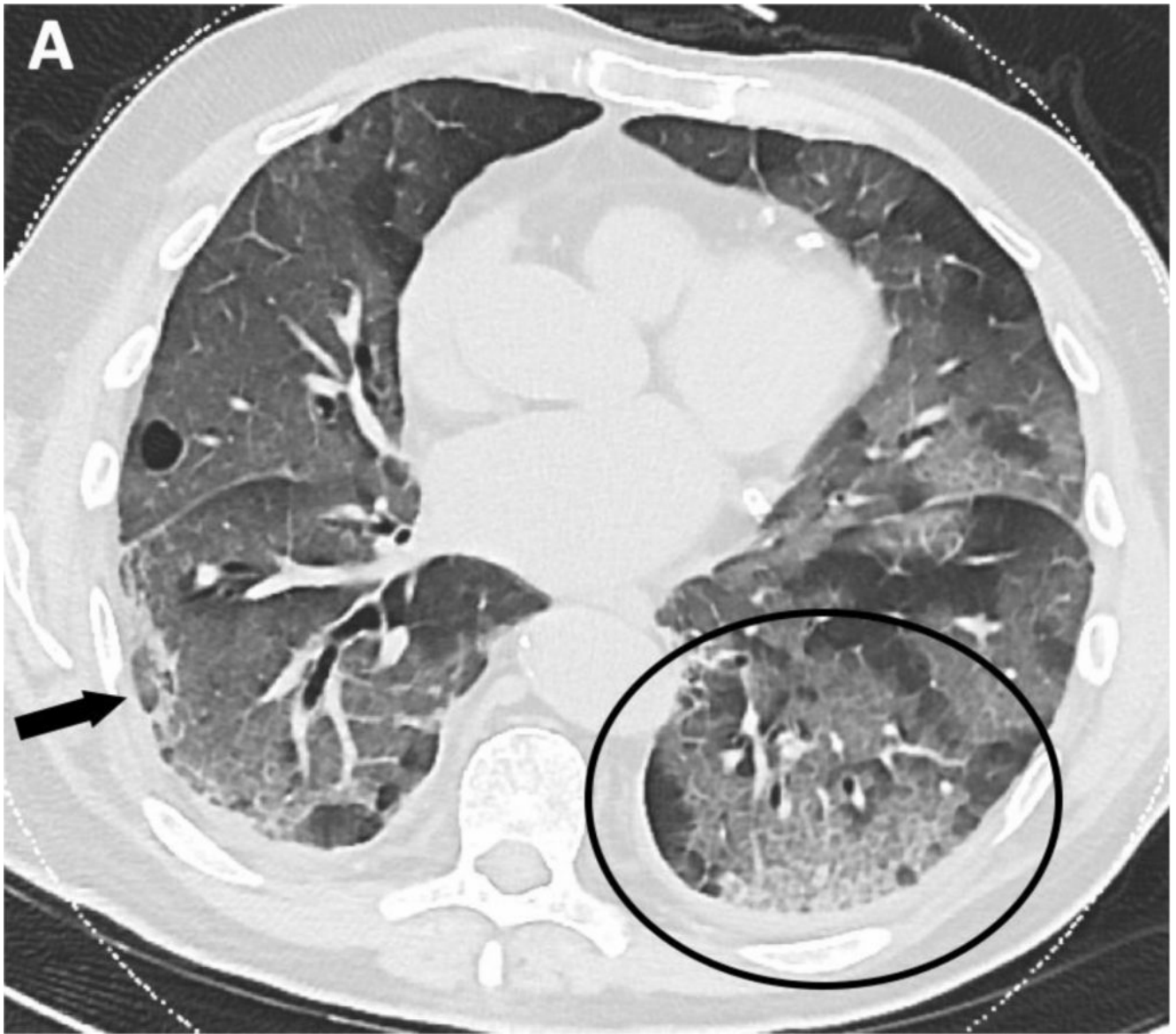
A. Borgheresi, A. Agostini, L. Ottaviani, C. Floridi, A. Giovagnoni

Dipartimento di Scienze Radiologiche – Scuola di  
Specializzazione in Radiologia

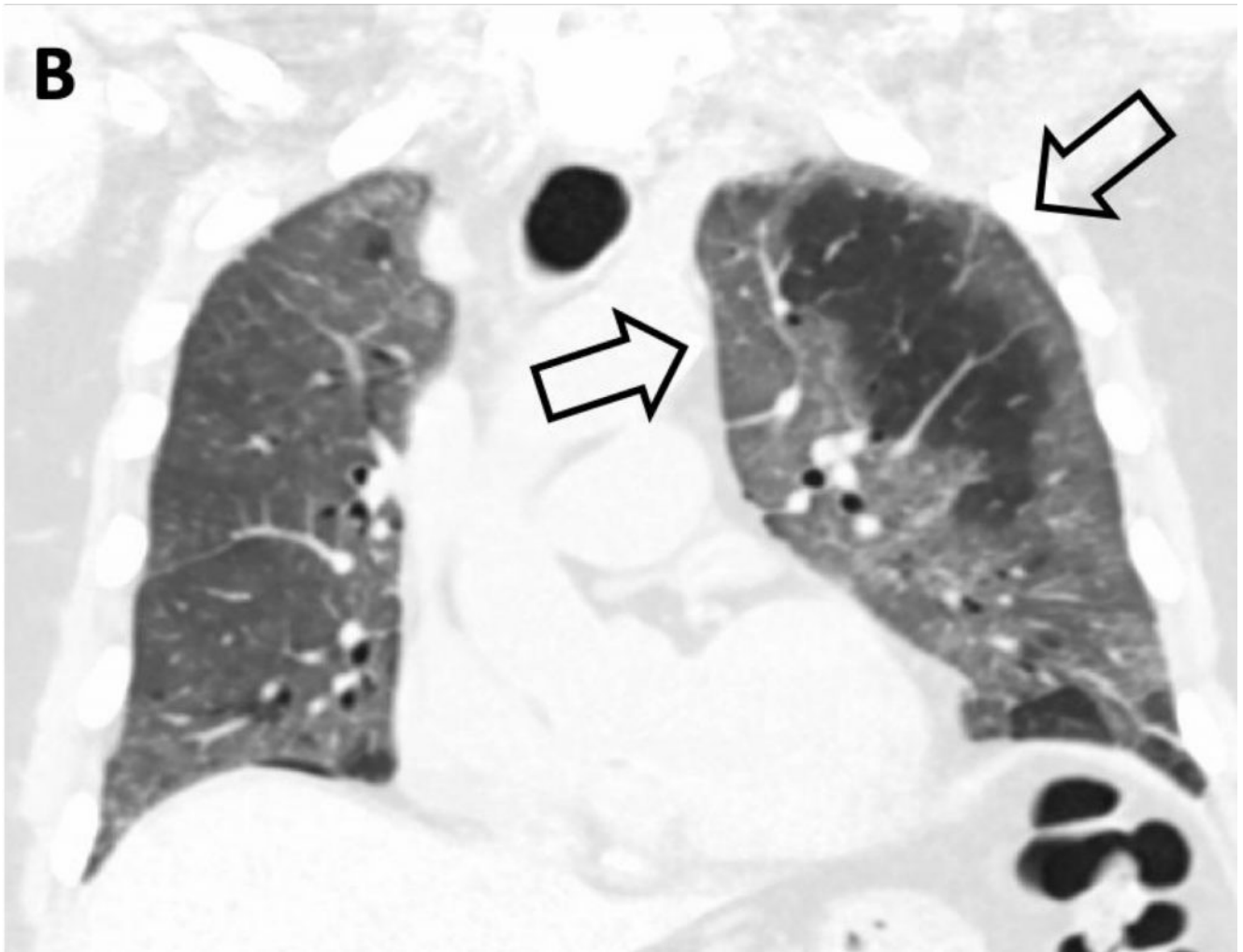
Università Politecnica delle Marche – Azienda Ospedali Riuniti  
– Torrette – Ancona

80-year-old male patient with fever and dyspnea. Nasal swab  
positive for SARS-CoV-2.

HRCT



Multiple ground-glass opacities associated with reticulations in a “crazy-paving pattern” (black circle) – particularly in the lower lobes. Subpleural consolidation (black arrow).



In the coronal view, the peripheral distribution of the GGOs is seen (arrows)